

Case Report

Functional retrocaval paraganglioma: A case report

Debansu Sarkar,¹ Mrinal Tandon,¹ Dilip Kumar Pal^{1*}

Department of Urology, Institute of Post Graduate Medical Education and Research (IPGME&R), Kolkata

Cite as: Sarkar D, Tandon M, Pal DK. Functional retrocaval paraganglioma: A case report: A Case report. J Pediatr Adolesc Surg. 2021; 2: Ahead.

This is an open-access article distributed under the terms of the Creative Commons Attribution License, which permits unrestricted use, distribution, and reproduction in any medium, provided the original work is properly cited (<https://creativecommons.org/licenses/by/4.0/>).

ABSTRACT

Background: Functional paragangliomas are one of the rare and curable causes of secondary hypertension. Its usual location is in the region of the head and neck but is rarely seen in the retrocaval region.

Case Presentation: We present a rare case of an 18-year-old young boy who presented with functional retrocaval paraganglioma. The Imaging workup revealed a 6cm mass abutting the inferior vena cava (IVC). The mass was successfully excised. Histopathology showed it was a paraganglioma.

Conclusion: Retroperitoneal retrocaval paragangliomas are rarely seen tumors with very few cases reported so far. The location of paragangliomas in this region is usually uncommon and its surgical resection is itself a challenge for the surgeon. Complete surgical resection with prior adequate hypertension control is the only curative treatment of paragangliomas. Lifelong follow-up is necessary to detect early recurrence.

Keywords: Functional, Paraganglioma, Retrocaval, Surgical resection.

INTRODUCTION

Retroperitoneal paragangliomas are neuroendocrine tumors of extra-adrenal origin. These are the tumors that arise from the parasympathetic and sympathetic components of the autonomic nervous system. Paragangliomas are more common in males and the most common age of presentation is between 30–45 years. These tumors are most commonly found in the head and neck and are rarely seen in the retroperitoneum.[1] The incidence of extra-adrenal paragangliomas is not known and is found that it is 10% of adult pheochromocytomas.[2] Most of these tumors are hormonally active (functional). Functional paragangliomas are rare but curable causes of secondary hypertension. A case of an 18 years old young boy who presented with functional retrocaval paraganglioma is reported here.

CASE REPORT

An 18-year-old boy presented with complaints of intermittent palpitations associated with diaphoresis and episodic headache for the last 18 months. There was no history of significant weight changes, weakness of

muscles, or any history of thyroid surgery in the past with no signs of heat or cold intolerance. There was no family history of hypertension.

On clinical examination, the patient was hypertensive with blood pressure (BP) of 215/80 mm of Hg and the pulse rate was 94 beats per minute (bpm). The patient had resistant hypertension (BP remained uncontrolled on multiple drugs). The patient was admitted and thoroughly investigated. Complete hemogram and basic metabolic tests were normal. CT scan brain was carried out to rule out any intracranial lesion.

USG Abdomen with renal doppler revealed a hypochoic lesion 4.7 x 4.4 x 3.7 cm near the right renal hilum with no evidence of renal artery stenosis. He underwent a CECT abdomen which revealed well-defined, heterogeneously enhancing lesions 41 x 43 x 53 mm in the right paravertebral region in retrocaval location; medially abutting the IVC & anteriorly lifting the right renal vessels (Fig 1). Subsequently, his MRI abdomen revealed both kidneys were normal in shape, size, contour, outline & position. There was a well-defined, 2.7 x 4.4 x 5.4 cm, retroperitoneal T1 hypointense & T2 hyperintense SOL in the retrocaval region with extension

to pre & right paravertebral region with no bony erosions.

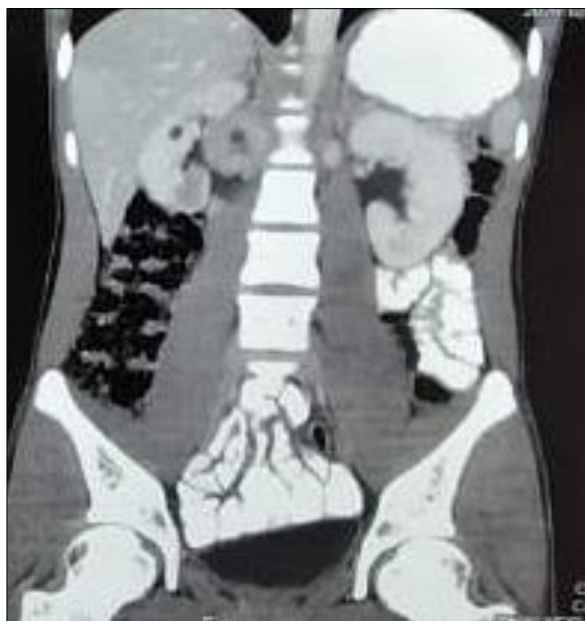

Figure 1: CECT abdomen showing heterogeneously enhancing lesion in right paravertebral region in retrocaval location

The patient underwent 24 hours of urinary fractionated catecholamine estimation which revealed urinary normetanephrine more than 4 times of ULN (24 hrs urinary nor- metanephrines - 4393.4 ug/ 24 hrs; Normal value <600 ug/ 24hrs). His USG Thyroid showed RL -12 mm, Isthmus - 2.7 mm, and LL - 11.5 mm with a 4x1mm ill-defined, hyperechoic area noted in the right lobe of the thyroid without taking any vascularity. His serum calcitonin was found to be normal (2.22 pg/ml; N: 0 - 11.5). Following this FDG PET was done which revealed FDG avid, 4.8 x 4.0 cm, necrotic mass in the retrocaval region (SUV max 16.21). The fat plane between the lesion & Right adrenal appeared indistinct & there was no evidence of metabolically active disease anywhere else in the body. Blood pressure was controlled by an endocrinologist by the combination of α and β -adrenergic blockers. The patient was on prazosin and the dose was titrated to achieve BP in the normal range. Later on, open surgical resection of the retroperitoneal mass was done.

The patient was adequately hydrated. The mass was excised through a midline abdominal incision after mobilization of ascending colon and small bowel from the ileocecal valve to the ligament of Treitz. A mass of approx. 6 cm size was found at the junction of the right renal vein and IVC (Fig 2). The mass was found abutting the right renal vein and right border of IVC. The mass was resected with adequate normal tissue all around (Fig 3). There were no complications intra-operatively or post-operatively. The blood pressure of the patient was normal in the immediate postoperative period and

remained within normal range with no antihypertensive medication needed until discharged from the hospital. He was discharged on the 7th postoperative day.

Histopathology of the specimen showed a tumor with the presence of spindle and polygonal cells with intense granular basophilic cytoplasm and the presence of moderate pleomorphism. The cells showed a trabecular and nested pattern which is a pathognomonic feature of paragangliomas. The tumor was encapsulated with no invasion of the capsule. Low mitotic activity was found. The patient was normotensive during his follow-up visits with normal urinary 24 hrs metanephrine levels.

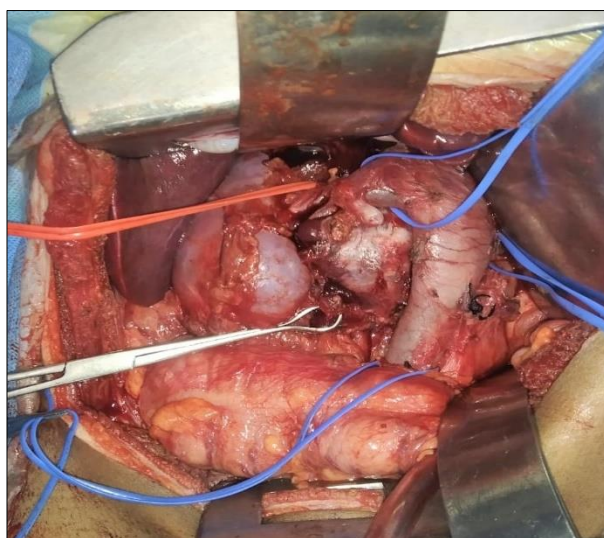


Figure 2: Mass of approx. size 6 cm at junction of right renal vein and IVC, abutting the right renal vein and right border of IVC

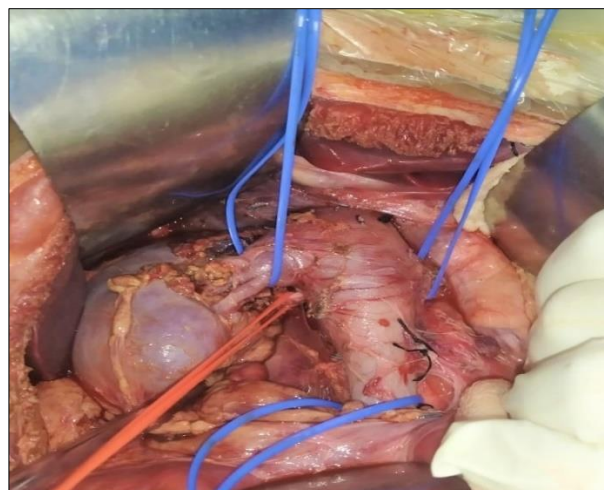


Figure 3: Area after resection of mass

The patient was on regular follow-up for 1 year without any adjuvant therapy. There was no evidence of any complications or recurrence. There were no signs of hypertension also.

DISCUSSION

Paragangliomas can be intra-adrenal paragangliomas or pheochromocytomas and extra-adrenal paragangliomas as per WHO classification of endocrine organs tumors [3]. The retroperitoneal paragangliomas exact incidence is unknown. The retroperitoneal paraganglioma diagnosis is difficult unless the tumor is functional. Hypertension is the most common presentation of functional paraganglioma. The common symptoms of paraganglioma include fever, palpitations, headache, and diaphoresis. Paragangliomas are seen mostly at a younger age, are more malignant, and have a higher risk of recurrence even after surgical excision when compared to pheochromocytomas. Paraganglioma secretes norepinephrine only while Pheochromocytoma secretes epinephrine and norepinephrine.

Paraganglioma is usually diagnosed with the findings of high levels of urinary catecholamine metabolites, VMA, and normetanephrine levels.[5] Retroperitoneal paragangliomas are not common. Retroperitoneal paragangliomas on CT scan show a homogenous mass with intense enhancement after contrast administration with sensitivity and specificity of 95–100% and 67% respectively in diagnosing retroperitoneal paragangliomas. MRI gives better information than a CT scan regarding the vascular structures adjacent to the mass. The sensitivity and specificity of MRI are 98–100% and 70% respectively in diagnosing retroperitoneal paraganglioma. 123I labelled MIBG scintigraphy has a sensitivity of 78% and a very high specificity of 100% for the diagnosis of paraganglioma. 131I can also be used as one of the therapeutic modalities in inoperable cases of malignant paraganglioma.[5,6] Retroperitoneal paraganglioma appears hypervascular with intralesional hemorrhage and necrosis frequently seen as the tumor grows on a CT scan.[7] On MRI, paragangliomas show high signal intensity or a light bulb bright signal on T2WI with the use of fat suppression and hypointense on T1WI.[8]

In our case, the patient presented with headache, tachycardia with refractory hypertension, and episodic sudden perspiration which is a classical triad of functional paraganglioma. Elevated Urinary catecholamine metabo-

lites especially metanephrines in the present case lead to the diagnosis of functional paraganglioma. The cases of paragangliomas with malignant transformation are well present and their only confirmed to be malignant is through the histological presence of metastasis of malignant cells. Paragangliomas are found to be more malignant than adrenal pheochromocytomas (35% vs. 10%).[9]

The present case is of benign paraganglioma and a PET scan confirmed the absence of metastasis in other parts of the body. The treatment of choice for paraganglioma is surgery. Optimal preparation of the patient with α and β blockers is very essential before surgical excision in order to avoid an intraoperative hypertensive crisis. After adequate preoperative preparation of the patient in view of hypertension, complete surgical removal of the tumor was done. Histopathology showed trabeculated and nested cells and this is the typical pathognomonic feature of paraganglioma. Postoperative follow up of patients for a longer period is necessary in order to detect early disease recurrence if present which is usually reported in more than 15% of cases even after 10 years.[10]

To conclude, retroperitoneal retrocaval paragangliomas are rarely seen tumors with very few cases reported so far. Retroperitoneal retrocaval location of paragangliomas is not very common and surgical resection is itself a challenge for operating surgeons. The only curative treatment is the complete surgical resection with prior adequate hypertension control. Lifelong follow-up is required to detect early recurrence.

Conflict of Interest: Nil

Source of Support: Nil

Consent to Publication: Author(s) declared taking informed written consent for the publication of clinical photographs /material (if any used), from the legal guardian of the patient with an understanding that every effort will be made to conceal the identity of the patient, however it cannot be guaranteed.

Authors Contribution: Author(s) declared to fulfill authorship criteria as devised by ICMJE and approved the final version. Authorship declaration form, submitted by the author(s), is available with the editorial office.

Acknowledgements: None

REFERENCES

1. He J, Wang X, Zheng W, Zhao Y. Retroperitoneal paraganglioma with metastasis to the abdominal vertebra: A case report. *Diagn Pathol* 2013; 8:52.
2. Goel N, Gupta N, Nag HH, Saran RK, Mishra PK. Nonfunctional retroperitoneal paraganglioma: A Histological surprise. *World J Endocr Surg* 2012; 4:60-2.
3. DeLellis RA, Lloyd RV, Heitz PU, Eng C. WHO classification of tumours. Pathology and genetics of tumours of endocrine organs. Lyon: IARC. 2004; 736.
4. Lloyd RV, Sisson JC, Shapiro B, Verhofstad A. Immunohistochemical localization of epinephrine, norepinephrine, catecholamine-synthesizing enzymes, and chromogranin in neuroendocrine cells and tumors. *Am J Pathol* 1986; 125:45-54.
5. Kaltsas GA, Besser GM, Grossman AB. The diagnosis and medical management of advanced neuroendocrine tumors. *Endocr Rev*. 2004; 25:458-511.
6. Sisson JC, Frager MS, Valk TW, Gross MD, Swanson DP, Wieland DM, et al. Scintigraphic localization of pheochromocytoma. *N Engl J Med* 1981; 305:12-17.
7. Mhanna T, Pianta E, Bernard P, Hervieu V, Partensky C. Preaortic paraganglioma mimicking a hypervascular tumor of the pancreas. *Hepato-gastroenterology*. 2004; 51:1198-201.
8. Shen Y, Zhong Y, Wang H, Ma L, Wang Y, Zhang K, Sun Z, Ye H. MR imaging features of benign retroperitoneal paragangliomas and schwannomas. *BMC Neurol*. 2018; 18:1-8.

Functional retrocaval paraganglioma: A case report

9. Scholz T, Eisenhofer G, Pacak K, Dralle H, Lehnert H. Clinical review: Current treatment of malignant pheochromocytoma. *J Clin Endocrinol Metab.* 2007; 92:1217–25.
10. Khorram-Manesh, Ahlman H, Nilsson O, et al. Long term outcome of a large series of patients surgically treated for pheochromocytoma. *J Intern Med.* 2005; 258:55–6.