

Clinical Vignette

Pyloric stenosis in the early neonatal period

Sadia Asmat Burki,¹ Sana Razzaq,^{*2} Muhammad Zain Anwar,² Muhammad Amjad Chaudary³

1. Consultant Pediatric Surgery, PIMS, Islamabad

2. House officer, Akbar Niazi Teaching Hospital (ANTH), Islamabad

3. Professor and Chair Neonatal and Pediatric Surgery, The Children's Hospital, PIMS, Islamabad

Cite as: Burki SA, Sana, Anwar MZ, Chaudary MA. Pyloric stenosis in the early neonatal period. *J Pediatr Adolesc Surg.* 2021; 2: Ahead.

This is an open-access article distributed under the terms of the Creative Commons Attribution License, which permits unrestricted use, distribution, and reproduction in any medium, provided the original work is properly cited (<https://creativecommons.org/licenses/by/4.0/>).

CASE PRESENTATION

A 4-day-old male patient presented in the emergency department with a history of reluctance to feed and vomiting since birth. The vomiting was non-projectile and non-bilious. The patient also had a history of not passing stool for the last two days. The patient initially passed meconium normally for the first two days. At the presentation, the newborn weighed 3.1 kg, and was febrile, icteric, and irritable but had no pallor or dehydration. Abdominal examination revealed a soft, non-tender abdomen without any palpable masses. A dry, empty rectum was observed on the digital rectal exam. Other systemic examinations were unremarkable. Laboratory investigations revealed normal electrolytes, hyperbilirubinemia, and an increased creatinine level.

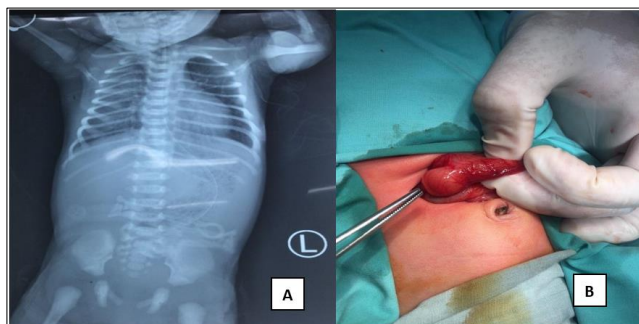


Figure 1: A) Single, large air bubble on plain x-ray, B) Showing hypertrophied pylorus.

A single, large air bubble was evident on a plain x-ray of the erect abdomen (Fig. 1A). Ultrasound of the abdomen demonstrated the gastric pylorus appearing thickened and giving a target sign on the transverse axis. The pyloric length was measured at 16.5mm. The thickness of the pyloric muscle was 5.5mm and the pyloric diameter was 12mm. Features suggested for neonatal

hypertrophic pyloric stenosis. Ramstedt's Pyloromyotomy (Fig. 1) was performed. The following findings were recorded; a thickened large pylorus, a distended stomach, and a duodenojejunal junction on the right side, normal ileo-cecal junction, and normal mesentery. The patient recovered well postoperatively and was discharged on the second postoperative day. The patient is doing fine on follow-up.

DISCUSSION

Mostly the patients with hypertrophic pyloric stenosis (HPS) present between 3 and 6 weeks of age. Although incredibly rare, neonates have been reported to have hypertrophic pyloric stenosis. An autopsy revealed pyloric stenosis (PS) in the 7-month-old fetus who was the youngest patient. Although 5% (range, 0.7-20%) of these patients experienced symptoms at birth, as noted by Zenn and Redo, there have been remarkably few cases of surgical intervention within the first week of life. [1] Early neonatal pyloric stenosis is accounted for as a congenitally produced soft hypertrophy of the pyloric muscle without the constriction consequences proposed by Wallgren. [2] Although the fundamental cause is still unknown, it is commonly known that PS is caused through a polygenic mode of inheritance with alterations caused by several environmental factors. [3] It has been demonstrated that bottle feeding, younger maternal age, maternal smoking, and erythromycin medication during the first two weeks of infancy are associated with this condition. The concept of familial aggregation has been articulated, and 47.9% of siblings have a family history. [4]

HPS is typically diagnosed with abdominal ultrasound, which reveals increased pyloric muscle thickness, length, and diameter. Laboratory analysis typically reveals a metabolic alkalosis that is hypochloremic and

hypokalemic and is caused by the loss of significant amounts of stomach hydrochloric acid. The severity of this condition relies on how prolonged symptoms persisted before the initial diagnosis. [5] That's why typical electrolytes and acid-base derangements were not observed in the index case. Since 1912, the Ramstedt pyloromyotomy has been the recommended procedure as also employed in our patient.

Conflict of Interest: Nil

Source of Support: Nil

Consent to Publication: Author(s) declared taking informed written consent for the publication of clinical photographs

/material (if any used), from the legal guardian of the patient with an understanding that every effort have been made to conceal the identity of the patient, however it cannot be guaranteed.

Authors Contribution: Author(s) declared to fulfill authorship criteria as devised by ICMJE and approved the final version. Authorship declaration form, submitted by the author(s), is available with the editorial office.

Acknowledgements: The authors would like to thank Maham Jahangir for his help in literature review.

REFERENCES

1. Chan SM, Chan EK, Chu WC, Cheung ST, Tam YH, Lee KH. Hypertrophic pyloric stenosis in a newborn: a diagnostic dilemma. *Hong Kong Med J.* 2011; 17:245-7.
2. Rollins MD, Shields MD, Quinn RJ, Wooldridge MA. Pyloric stenosis: congenital or acquired? *Arch Dis Childhood.* 1989; 64:138-9.
3. Kamata M, Cartabuke RS, Tobias JD. Perioperative care of infants with pyloric stenosis. *Pediatric Anesthesia.* 2015; 25:1193-206.
4. Galea R, Said E. Infantile hypertrophic pyloric stenosis: an epidemiological review. *Neonatal Network.* 2018; 37:197-204.
5. Chalya PL, Manyama M, Kayange NM, Mabula JB, Massenga A. Infantile hypertrophic pyloric stenosis at a tertiary care hospital in Tanzania: a surgical experience with 102 patients over a 5-year period. *BMC Res Notes.* 2015; 8:1-6.