J Pediatr Adolesc Surg. 2025; 3: 26-29
DOI: https://doi.org/10.46831/jpas.v2i2.169

OPEN ACCESS

Review Article

Laparoscopy in disorders of sex development: Diagnostic and therapeutic implications

Palak Singhai,[1] Shailesh Solanki,[*1] Ravi Prakash Kanojia[1]

Department of Pediatric Surgery, Postgraduate Institute of Medical Education and Research, PGIMER, Chandigarh, India

Cite as: Singhai P, Solanki S, Kanojia RP. Laparoscopy in disorders of sex development: Diagnostic and therapeutic implications. J Pediatr Adolesc Surg. 2025; 3: 26-29.

This is an open-access article distributed under the terms of the Creative Commons Attribution License, which permits unrestricted use, distribution, and reproduction in any medium, provided the original work is properly cited (https://creativecommons.org/ licenses/by/4.0/).

ABSTRACT

Disorders of Sex Development (DSD) comprise a broad spectrum of hormonal, chromosomal, and metabolic abnormalities that result in abnormal genital development. Every aspect of DSD, starting from diagnosis to treatment, is a challenge to the clinician. Standard evaluation with karyotyping, hormonal assays, and imaging may not be sufficient to categorize the type of DSD, due to overlapping clinical presentation across the spectrum. Laparoscopic visualization provides an accurate picture of the gross morphology of the gonads and the mullerian structures. Laparoscopy also serves as a tool for therapeutic intervention, while ensuring maximal cosmesis. Herein we aim to discuss the role of laparoscopy as a preferred diagnostic and therapeutic modality in DSD patients.

Keywords: Disorders of Sex Development, laparoscopy, pseudohermaphrodite

INTRODUCTION

Disorders of sex development (DSD) include a heterogeneous group of rare congenital conditions in which the development of chromosomal, gonadal or anatomical sex is atypical. The incidence of DSD has been reported to be between 1:3000 to 1:5000 live births. [1] The field of DSD was plagued by a lack of uniformity in description and terminology for decades. In 1976, Allen proposed a classification based on gonadal histology to categorize the types of DSD. [2] The terminology has now been replaced by more inclusive nomenclature. At present, three major categories of developmental aberrations are recognized based on the pathophysiology.

1. 46, XX DSD (Over-androgenization of genetic females)
2. 46, XY DSD (Under-virilization of the male)
3. Abnormalities of gonadal development and differentiation

To reduce the possibility of therapeutic misconduct or erroneous gender assignment, a comprehensive clinical evaluation is essential. The basic tenets of diagnosis are the karyotype and the presence or absence of gonadal symmetry. These are aided by sex hormone level assays, gene defect sequencing, and fluorescent in situ hybridization (FISH). Gonadal symmetry is determined on physical examination, cross-sectional imaging and by direct visualization using laparoscopy. Laparoscopy is an indispensable adjunct in providing crucial anatomical information for formulation of the management plan.

The advantages of laparoscopy are well known. The absence of a significant laparotomy incision reduces postoperative pain, the requirement for analgesia, the length of hospital stay, the length of convalescence, and the time it takes to resume normal daily activities. For the surgeon, laparoscopy provides an improved, magnified view of the pelvic organs. [3]

Literature review

Since the first report of laparoscopic bilateral gonadectomy in an intersex patient in 1992, laparoscopy has steadily become an integral element in the diagnosis and surgical management of these patients. [4] Recent case reports and series (Table 1) have further substantiated the role of laparoscopy in careful

Correspondence*: Dr. Shailesh Solanki, Room no 5422, D block, 5th floor, Advanced Pediatric Centre, PGIMER, Sector 12, Chandigarh, Pin- 160012, India
Email: drshaileshpgi@gmail.com
Submitted on: 27-03-2023
© 2025, Singhai et al,
Accepted on: 29-11-2023

evaluation, correct gender assignment and surgical management of these patients. [5-9]

Table 1: Review of literature on the role of laparoscopy in diagnosis and management of disorders of sex development

Serial Number	Authors	Number of patients	Diagnosis	Laparoscopic Procedures Performed
1.	Moriya K, et al [5]	25	Ovo - testicular DSD, MGD, AIS, CAH	10 diagnostic laparoscopies; 19 therapeutic procedures including 17 gonadectomies, 2 hysterectomies, 1 orchiopexy, and 1 sigmoid vaginoplasty
2.	Burgmeier C, et al [6]	12	MGD, PGD, 5-alpha reductase deficiency	12 diagnostic laparoscopies,7 gonadectomies, 3 gonadopexies, 1 removal of utriculus
3.	Goultaiene A, et al [7]	4	Ovo-testicular DSD, 5 alpha reductase deficiency, MGD	Gonadal biopsy, gonadectomy, bilateral orchidopexy
4.	Galván-Montaño A, et al [8]	1	PMDS	Excision of mullerian remnants+ orchiopexy
5.	Costamilan Rombaldi M, et al [9]	1	Ovo testicular DSD	Partial gonadectomy (gonad-sparing surgery)

DSD = disorders of sex development; MGD = Mixed Gonadal Dysgenesis; AIS = Androgen insensitivity syndrome; CAH = Congenital Adrenal Hyperplasia; PGD = Pure Gonadal Dysgenesis; PMDS = Persistent Mullerian Duct Syndrome

Indications for laparoscopy in DSD:

The indications for laparoscopy can be diagnostic or therapeutic. They can be divided into five broad categories:

1) To visualize the internal pelvic anatomy – Laparoscopy can be utilized to localize gonads in cryptorchidism, and to identify persistent mullerian structures in Mixed Gonadal Dysgenesis (MGD).

2) Biopsy of gonads – Diagnostic gonadal biopsy can be performed laparoscopically in patients with suspected MGD or ovo-testicular DSD.

3) Gonadectomy – Laparoscopic gonadectomy can be performed for dysplastic and malignant gonads in MGD and Pure Gonadal Dysgenesis (PGD).

4) Excision of organs contrary to the assigned sex – Laparoscopy can be utilized for the removal of mullerian structures in persistent mullerian duct syndrome (PMDS), gonad contrary to the assigned sex in Ovo-testicular DSD, and the removal of prostatic utricle in patients with recurrent urinary tract infections.

5) Reconstruction – Laparoscopy-assisted vaginal reconstruction can be performed in congenital adrenal hyperplasia. Laparoscopic orchiopexy is commonly practiced in patients with partial androgen insensitivity syndrome (PAIS) or 5-alpha reductase deficiency.

Laparoscopy in 46XX DSD (Previously referred to as Female Pseudohermaphrodite):

The most common causes of over-androgenization of genetic females are congenital adrenal hyperplasia (CAH) and exogenous exposure to androgens. Laparoscopy has a limited role in these patients. Laparoscopic vaginal reconstruction (Vecchietti procedure or Davydov procedure), or laparoscopy- assisted mobilization of bowel for vaginal reconstruction can provide better cosmesis compared to open surgery. [10] Rarely, if the child presents in late adolescence and has been raised as a male, laparoscopic gonadectomy and excision of Mullerian Duct structures can be offered.

Laparoscopy in 46 XY DSD (Previously referred to as Male Pseudohermaphrodite):

The most common causes of under-virilization of genetic males are androgen synthesis defects, androgen receptor insensitivity, and 5-alpha reductase deficiency.

Laparoscopy is rarely indicated in complete androgen insensitivity syndrome (CAIS), as the testes are usually found within the inguinal canal. CAIS may be diagnosed incidentally in patients undergoing laparoscopic herniotomy, by the presence of a gonad as a content of the hernia sac, without the presence of a uterus. Such a gonad should be biopsied and replaced within the abdomen while awaiting the final diagnosis. Bilateral laparoscopic gonadectomy can be performed at a later stage once the diagnosis is confirmed with karyotype, sex hormone assays, and histopathology.

Testosterone synthesis defects, PAIS, and 5-alpha reductase deficiency present with a wide range of differentiation of the genitalia. In patients assigned male gender, laparoscopy can aid in localizing non-palpable, undescended testes, and in performing orchidopexy. In the case of female gender assignment, ablation of gonads can be performed laparoscopically.

Laparoscopy in abnormalities of sex chromosomes and gonadal differentiation

Sex chromosome anomalies present as absent, incomplete, or asymmetric differentiation of gonads. They include PGD, MGD, and ovo-testicular DSD.

i. Pure Gonadal Dysgenesis (PGD):

The appearance of these children at birth is unambiguously female. Usually, they manifest themselves during adolescence as pubertal failure. Due to the presence of chromosome Y, the risk of malignancy in the gonads is high. Laparoscopic bilateral gonadectomy is indicated in these patients.

ii. Mixed Gonadal Dysgenesis (MGD):

There are different patterns of karyotypes in MGD, but most commonly 45XO/46XX is observed. The presentation in MGD patients typically consists of one testicular gonad with an accompanying vas deferens, along with an undifferentiated streak gonad with adjoining Mullerian duct derivatives. Laparoscopy is a valuable tool in MGD to verify the pelvic anatomy, perform a gonadal biopsy, and excise genital structures as per the gender of rearing. Laparoscopy is the best approach for the removal of pelvic structures like persistent urogenital sinus, providing adequate exposure and minimizing tissue handling.

iii. Ovo-testicular DSD (previously referred to as True Hermaphrodite):

External genitalia are often asymmetrical, and chromosomal arrangements vary, although 46XX is the most common. Among the common varieties, there are intra-abdominal ovary, hemi-uterus, fallopian tube, and ovarian vessels on one side, and ovotestes with vas deferens and gonadal vessels on the other side. Laparoscopy enables the clinician to identify the nature of the gonad and perform procedures like gonadectomy or orchidopexy based on the gender chosen for rearing.

Persistent Mullerian duct syndrome (PMDS):

This is an uncommon anomaly characterized by phenotypically normal male external genitalia, associated with either a non-palpable testis or a hernia on the same side as a non-palpable testis (hernia uteri inguinale). It is often diagnosed incidentally during laparoscopy performed for either orchiopexy or herniotomy. The deep pelvis can be seen in great detail during laparoscopy, making it possible to locate the gonads and remove Mullerian duct remnants like the hypoplastic uterus and fallopian tubes. The vas deferens are often intimately adhered to the mullerian duct remnants, especially the hypoplastic vagina. Complete removal of the remnants can thus risk the integrity or vascularity of the vas deferens (Fig. 1). Extirpation or coagulation of the hypoplastic vagina's mucosa as low down as possible minimizes the risk of cancer while permitting the preservation of the vas and its vessels if safe excision is not achievable.

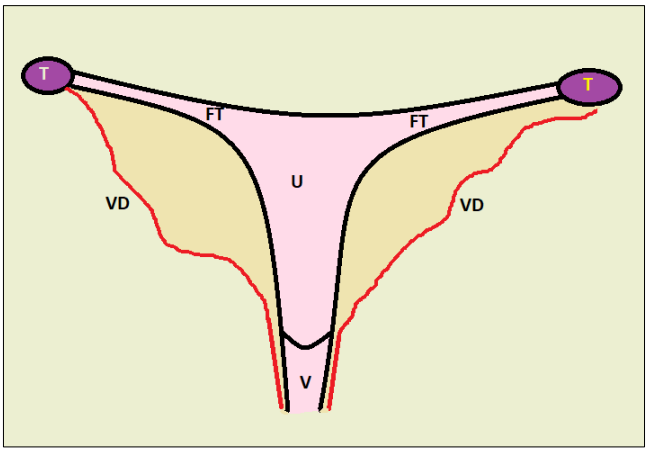

Figure 1: The close association of vas deferens with mullerian remnants in Persistent Mullerian Duct Syndrome. T= Testis, FT= Fallopian tube, U= Uterus, V= Vagina, VD= Vas Deferens

Surgical technique:

Preoperative - The child's external genitalia is carefully inspected and palpated. Bladder catheterization must be done to ensure the bladder is empty during laparoscopy. Genitoscopy is performed in cases where indicated, just prior to laparoscopy.

Patient's position- The patient is positioned supine. To elevate the pelvis, a towel roll is placed under the buttocks. The baby should be in the Trendelenburg position for better visualization of the pelvic anatomy.

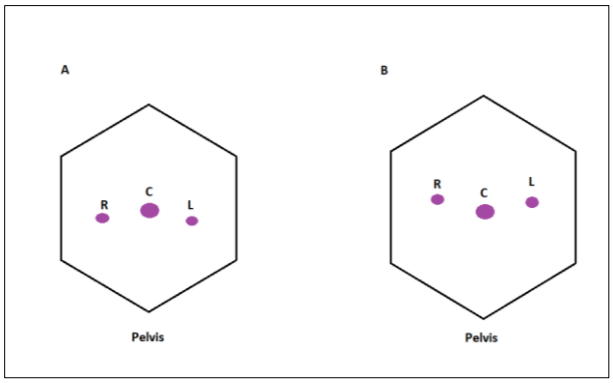

Figure 2: A) Port placement for diagnostic laparoscopy in disorders of sex development in children. B) Port placement in infants with disorders of sex development. C = Camera port, L= Left working port, R = Right working port

Port position- A trans umbilical incision with the Hasson technique of port placement allows insertion of the primary port under vision and the creation of a pneumoperitoneum. One working port of 3/5 mm each is placed on either side of the umbilicus. In infants, the working ports are placed more cranially in the abdomen to increase the available working space (Fig. 2). A transabdominal retracting suture can be placed if the

urinary bladder is obstructing the view of the pelvic organs.

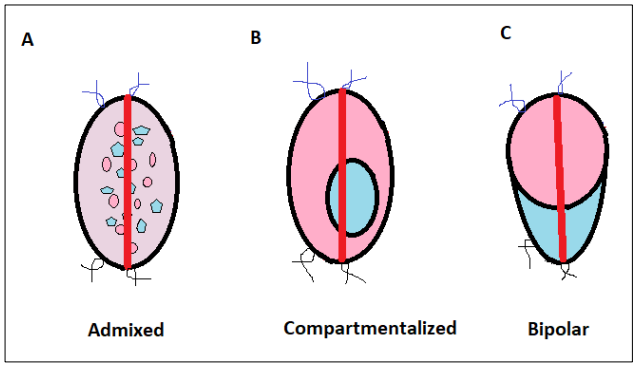

Figure 3: Deep, full-length longitudinal biopsy with marking of poles using different colour sutures ensures adequate sampling in different arrangements of ovo-testes. (Red line represents the biopsy tract; pink and blue are representative of ovarian and testicular tissue respectively)

Procedure- The pelvic anatomy can be examined to determine the nature of the gonads and the level of differentiation of the genital ducts. The fundus of the uterus is grasped and turned to check the location of the gonads and the fallopian tube. Generally, the streak gonad and fallopian tube are located adjacent to one another. Diathermy scissors or bipolar diathermy can be used to remove a streak gonad. If an ovotestis is suspected, a full-length, deep longitudinal biopsy should be taken, and the two poles should be marked with different colour sutures (Fig. 3). Marking helps to identify the ovarian and testicular tissue during subsequent surgery to allow a hemi-gonadectomy if required.

When the diagnosis is uncertain even on laparoscopy, it is acceptable to end the surgery after taking adequate biopsies and creating a thorough photographic record. Once histopathology is available, a multidisciplinary discussion may be beneficial to arrive at the diagnosis.

CONCLUSION

In patients with DSD, laparoscopic visualization and diagnostic biopsy are important adjuncts in forming a road map for the therapeutic strategy. Dysgenetic, malignant, or potentially malignant gonads, and pelvic organs contrary to the assigned sex, can be resected laparoscopically with improved vision, cosmesis, and few complications. In selected cases, laparoscopic can also be used to aid reconstructive procedures.

Conflict of Interest: Nil

Source of Support: Nil

Consent to Publication: Author(s) declared taking informed written consent for the publication of clinical photographs /material (if any used), from the legal guardian of the patient with an understanding that every effort will be made to conceal the identity of the patient, however it cannot be guaranteed.

Authors Contribution: Author(s) declared to fulfill authorship criteria as devised by ICMJE and approved the final version. Authorship declaration form, submitted by the author(s), is available with the editorial office.

Acknowledgements: None

REFERENCES

1. Hamin JN, Arkoncel FR, Lantion-Ang FL, Sandoval MAS. 46 XY gonadal dysgenesis in adulthood 'pitfalls of late diagnosis'. BMJ Case Rep. 2012; 2012: bcr1220103626.
2. Allen TD. Disorders of sexual differentiation. Urology.1976; 7:1–32.
3. Chertin B, Koulikov D, Alberton J, Hadas-Halpern I, Reissman P, Farkas A. The use of laparoscopy in intersex patients. Pediatr Surg Int. 2006; 22:405-8.
4. Dénes FT, Cocuzza MA, Schneider-Monteiro ED, Silva FA, Costa EM, Mendonca BB. The laparoscopic management of intersex patients: the preferred approach. BJU Int. 2005; 95:863-7.
5. Moriya K, Morita K, Mitsui T, Kitta T, Nakamura M, Kon M, et al. Impact of laparoscopy for diagnosis and treatment in patients with disorders of sex development. J Pediatr Urol. 2014; 10:955–61.
6. Burgmeier C, Leriche C. Laparoscopy in the surgical treatment of disorders of sexual development. J Laparoendosc Adv Surg Tech. 2016; 26:730–3.
7. Goultaiene A, Elmortaji K, Sentissi R, Moataz A, Rabii R, Aboutaib R, et al. Role of laparoscopy in the management of the abnormalities of sex differentiation: about 12 cases. Pan Afr Med J. 2016; 23:167.
8. Galvan-Montano A, Maya-Barrios JA, Parraguirre-Martínez S, Jiménez-Ferreira MA, Baca-Patiño RA, García-Moreno S. Laparoscopía en el diagnóstico de síndrome de persistencia del conducto de Müller en un escolar con escroto vacío. Rev Mex Pediatría. 2020; 87:102–5.
9. Rombaldi MC, da Silva Azenha MV, de Paula LCP, Loguércio Leite JC, Hemesath TP, Carvalho C, et al. Laparoscopic gonad-sparing procedure in Ovotesticular disorder of sex development - Case video technique. J Pediatr Urol. 2021; 17:583–4.
10. Ismail IS, Cutner AS, Creighton SM. Laparoscopic vaginoplasty: alternative techniques in vaginal reconstruction. BJOG. 2006; 113:340-3.