

Clinical Vignette

Congenital laryngeal cyst causing repeated airway obstruction in a six-year-old girl

Abdolhamid Amooee,¹ Farzan SafiDahaj,^{2*} Shokouh TaghipourZahir,³ Arezoo AlamdarYazdi¹

1 Department of Surgery, Shahid Sadoughi Hospital, Shahid Sadoughi University of Medical Sciences, Yazd, Iran

2 Student Research committee, Shahid Sadoughi Hospital, Shahid Sadoughi University of Medical Sciences, Yazd, Iran

3 Department of Pathology, Shahid Sadoughi Hospital, Shahid Sadoughi University of Medical Sciences, Yazd, Iran

Cite as: Amooee A, SafiDahaj F, Congenital laryngeal cyst causing repeated airway obstruction in a six-year-old girl. J Pediatr Adolesc Surg. 2024; 2:61-2.

This is an open-access article distributed under the terms of the Creative Commons Attribution License, which permits unrestricted use, distribution, and reproduction in any medium, provided the original work is properly cited (<https://creativecommons.org/licenses/by/4.0/>).

CASE PRESENTATION

A six-year-old female was admitted to the pediatric ward with a chief complaint of respiratory distress after having a cold. She had no history of NICU admission or any history of intervention or manipulations done to the airway. During the neonatal period, she did not show signs of any breathing problems until the 5th month of age. From then on, she started suffering from mild distress during sleep, and other symptoms indicating an obstruction including orthopnea and sensitivity to some allergens like smoke and perfume, which all started to develop gradually. On examination, she weighed 18kg and was 112cm in height, which indicated a failure to thrive with otherwise normal development. On admission, she looked distressed without any sign of tachypnea or cyanosis. However, the use of accessory respiratory muscles was evident. Suspected as an asthma patient, she was conservatively treated with corticosteroid and salbutamol spray. However, the symptoms were not relieved completely. Also, a chest x-ray was done to rule out foreign body aspiration, and infectious diseases, but the radiograph did not show any abnormality of the lower respiratory system. Consultation with an ENT specialist was requested, and subsequently, a bronchoscopy was performed, which revealed a subglottic mass, and suspicion of hemangioma. With suspicion of infection and hemangioma, medical therapy with Inderal and Methylprednisolone, and Ceftriaxone was suggested. Furthermore, a CT scan was performed to look for more diagnostic options, which showed a hypodense mass in

the anterior subglottic area of larynx, with a diameter of 15mm, suspicious of being a thyroglossal or other forms of cystic lesion (Fig. 1).

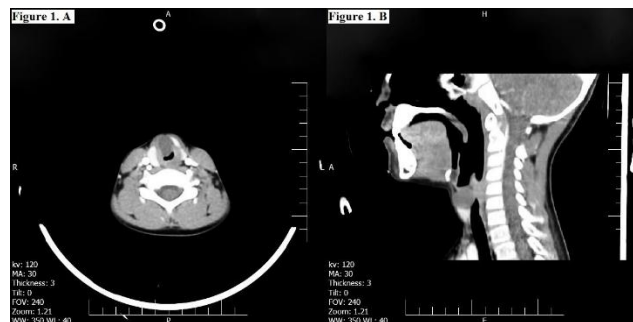


Figure 1: Computed tomography showing a hypodense mass in the anterior subglottic area of larynx, with a diameter of 15mm. The lesion can be seen in (A) Axial view and (B) Sagittal view

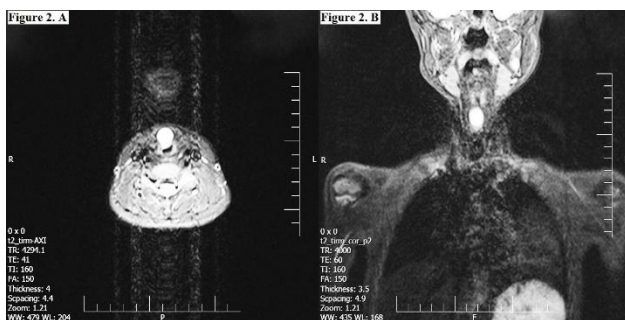

Figure 2: T2-weighted MRI findings. The congenital laryngeal cyst is seen as a hyperintense lesion in the axial section (A) and coronal view (B).

After consulting with a surgeon, the patient underwent an MRI (Fig. 2), and the reported differential diagnosis included lymphangioma, hemangioma, and dermoid cyst. After informed consent, patient was explored through a transverse incision on neck. Strap muscles were divided and a well-defined cystic like lesion was exposed. During mass removal, an incision was made through the cricothyroid membrane to dissect the lesion completely. After the mass removal, using Vicryl 5-0 suture the cricothyroid membrane was repaired. Consistent with the pathologist report, sections revealed fibrovascular connective tissue with cystic spaces lined by respiratory like epithelial cells which were compatible with laryngeal cyst (saccular type) (Fig. 3).

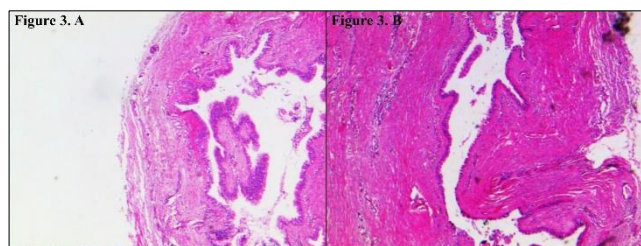


Figure 3: Fibrovascular connective tissue with cystic space lined by respiratory epithelium. (A) H&E staining method. 10× Magnification, (B) 20× Magnification.

DISCUSSION

Most common congenital laryngeal anomalies consist of laryngomalacia, subglottic stenosis, and vocal cord paralysis while congenital laryngeal cyst is the rare one with an annual incidence of 1.8 per 100,000 live births.[1-3] It remains uncertain if any subglottic cysts arise as a primary congenital pathology without previous airway manipulation. Additionally, intubation remains the main means of ventilator support in extremely premature neonates; therefore it is important to highlight its potential consequence in the genesis of subglottic cysts.[4,5] Our case didn't have any history of admission at NICU and airway manipulation.

REFERENCES

- Balakrishnan K. Pediatric laryngeal anomalies. *Curr Treat Options Pediatr.* 2018; 4:183–202. Available from: <https://doi.org/10.1007/s40746-018-0120-5>.
- D'heygere E, Vauterin T, Casselman JW, Kuhweide R, Dick C. Congenital laryngeal cyst: an unusual cause of stridor in the neonate. *B-ENT.* 2016; 11:313–7. Available from https://www.unboundmedicine.com/medline/citation/26891546/Congenital_laryngeal_cyst:_an_unusual_cause_of_stridor_in_the_neonate.
- See GB, Mesran I. Stridor secondary to acquired subglottic cyst: Rarity makes it missed. *Indian J Otolaryngol Head Neck Surg.* 2019; 71:45–8. Available from: <https://doi.org/10.1007/s12070-016-0992-2>.
- Agada FO, Bell J, Knight L. Subglottic cysts in children: a 10-year review. *Int J Pediatr Otorhinolaryngol.* 2006; 70:1485–8. Available from: <https://doi.org/10.1016/j.ijporl.2006.03.010>
- Forte V, Fuoco G, James A. A new classification system for congenital laryngeal cysts. *Laryngoscope.* 2004; 114:1123–7. Available from: <https://onlinelibrary.wiley.com/doi/abs/10.1097/00005537-200406000-00031>.
- Lim EH, Mohamad H, Sheikh Ab Hamid S. Congenital laryngeal cyst: A report of 2 cases. *Egypt J Ear Nose Throat Allied Sci.* 2017; v18:187–9. Available from: <http://www.sciencedirect.com/science/article/pii/S2090074016300901>.
- Busuttill M, Einaudi M-A, Hassid S, Chau C, Shojai R, Thomachot L, et al. Congenital laryngeal cyst: Benefits of prenatal diagnosis and multidisciplinary perinatal management. *Fetal Diagn Ther.* 2004; 19:373–6. Available from: <https://www.karger.com/DOI/10.1159/0000779>

The congenital laryngeal cyst is often mistakenly diagnosed as other conditions such as laryngomalacia, asthma, and croup due to its manifestation as recurring respiratory infections, stridor, and wheezing.[6] In addition to the evidence of failure to thrive, our case showed stridor and dyspnea, and other symptoms of obstruction from 5th months after birth. The common location for this kind of cyst is the aryepiglottic fold, followed by the vallecula, the laryngeal ventricle, and the subglottic region; however, vallecula is considered the most common location.[7] The laryngeal cyst in our case was located in the subglottic area of the larynx. Diagnosis can be made via the clinical examinations and symptoms, but the crucial role of laryngoscopy, as the gold standard method, should be noted. Imaging techniques (CT scan and MRI) for evaluating the extra laryngeal extension and treatment guidance are used as well.[1, 6]

For lesions without extra-laryngeal extension, endoscopic excision with the cyst wall removal may be used, whereas in cases with extra-laryngeal extension or recurrences external approaches may be required. Seldom, to decompress the cysts and relieve the airway obstruction, needle-aspiration might be utilized.[6] In our case, the cyst was small in size but to reduce the risk of recurrence, and due to the unknown cause of hypodense mass she underwent open surgery.

Source of Support: Nil

Consent to Publication: Author(s) declared taking informed written consent for the publication of clinical photographs/material (if any used), from the legal guardian of the patient with an understanding that every effort have been made to conceal the identity of the patient, however it cannot be guaranteed.

Authors Contribution: Author(s) declared to fulfill authorship criteria as devised by ICMJE and approved the final version. Authorship declaration form, submitted by the author(s), is available with the editorial office.

Acknowledgements: None