

## Case Report

### Laparoscopic management of a giant challenging ovarian dermoid cyst: A case report

Sangam Jha,<sup>1</sup> Akanksha Singh,<sup>2</sup> Upasna Sinha,<sup>3</sup> Jayanti Sinha<sup>4</sup>

1 MS, Associate Professor, department of obstetrics and gynecology, AIIMS Patna, Bihar, India.

2 Junior resident, department of obstetrics and gynecology, AIIMS Patna, Bihar, India.

3 Associate Professor, department of Radiodiagnosis, AIIMS Patna, Bihar, India.

4 Resident, department of obstetrics and gynecology, AIIMS Patna, Bihar, India.

**Cite as:** Jha S, Singh A, Sinha U, Sinha J. Laparoscopic management of a giant challenging ovarian dermoid cyst: A case report. J Pediatr Adolesc Surg. 2024; 2: 112-14.

This is an open-access article distributed under the terms of the Creative Commons Attribution License, which permits unrestricted use, distribution, and reproduction in any medium, provided the original work is properly cited (<https://creativecommons.org/licenses/by/4.0/>).

## ABSTRACT

**Background:** Dermoid cyst accounts for 10-20 % of all ovarian tumors. Traditionally giant ovarian cysts have been removed through a midline laparotomy. Here we report a case of laparoscopy-assisted removal of a giant dermoid cyst in an adolescent girl.

**Case Presentation:** A 17-year-old girl presented with a complaint of abdominal distension for 7 months. Abdominal examination revealed a well-defined tense cystic mass arising from the pelvis and extending up to the epigastric region. CT scan of abdomen and pelvis reported a mature teratoma of size 25.5x19.9x35cm of the right ovary. Laparoscopic excision of the cyst was performed following extracorporeal drainage of the cyst.

**Conclusion:** Laparoscopy-assisted removal of a giant ovarian dermoid cyst is a feasible mode of treatment irrespective of its size provided malignancy has been ruled out.

**Keywords:** Huge ovarian dermoid cyst, Laparoscopy, Extracorporeal drainage, Mature teratoma.

## INTRODUCTION

Dermoid cyst is the most common ovarian germ cell tumor in the reproductive years of the female accounting for 10-20 % of all ovarian tumors with 1-2% malignancy risk. [1] As the dermoid cysts are indolent tumors with a very slow growth rate of approximately 1.8mm/year, only a few cases of huge dermoid cysts are reported in the literature. [2] Though the dermoid cysts are usually asymptomatic and diagnosed incidentally on sonography, giant tumors can present with pressure symptoms like urinary complaints or respiratory embarrassment. [3] Traditionally giant ovarian cysts have been removed through a midline laparotomy. Here we report a case of laparoscopic removal of a giant dermoid cyst in an adolescent girl. This case report is an important addition to the literature, given the impressive

size of the cyst and its successful excision through the laparoscopic approach.

## CASE REPORT

A 17-year-old female of 48.6 kg weight, presented with a complaint of abdominal distension for 7 months that had insidious onset, firstly noticed in the lower abdomen now involving the whole abdomen. It was associated with significant weight and appetite loss. She attained menarche at 15-year of age and had regular cycles with normal flow. She had a history of fluid tapping from the swelling twice 2 months ago at the interval of 15 days with one liter of fluid aspirated each time. On examination her vitals were stable and she had a thin cachectic built. Abdominal examination revealed a well-defined tense cystic mass arising from the pelvis and extending up to the epigastric region.

Correspondence\*: Dr. Sangam Jha, Associate professor, department of obstetrics and gynecology, AIIMS Patna, Phulwarisharif, Patna, Bihar, India.

Email: [sangam.jha78@gmail.com](mailto:sangam.jha78@gmail.com)

Submitted on: 26-07-2021

© 2024, Jha et al,

Accepted on: 08-08-2021

CT scan of abdomen and pelvis showed a large abdominopelvic cystic mass of size 25.5x19.9x38.4cm with calcification and fat foci suggesting a mature teratoma arising from the right ovary (Fig. 1A, 1B). A laboratory workup overall was normal, including b-HCG, LDH, AFP, CEA, and CA 19 -9, except for a mildly elevated CA 125 (42.5 U/mL) and low Hb (9.3gm/dl). With the diagnosis of mature cystic teratoma, laparoscopic-assisted resection of the cyst was planned.

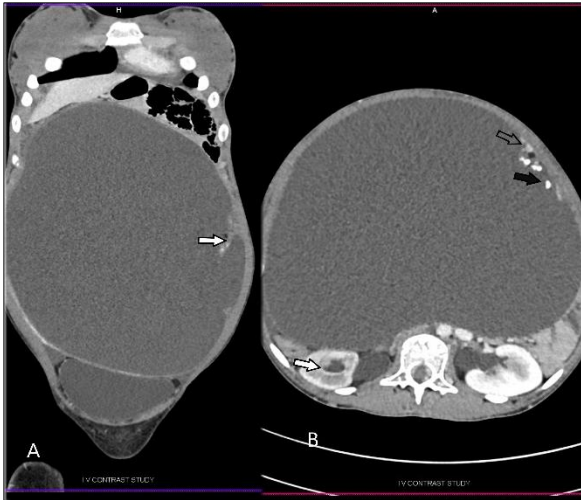


Figure 1: A) Coronal contrast-enhanced CT image shows a large thin-walled abdominopelvic cystic mass with a thick septae along its left lateral wall (white arrow). B) Axial contrast-enhanced CT image shows a large thin-walled cystic mass with few eccentric calcific foci (black arrow) and a focal fatty attenuation (hollow arrow). There is mild right hydronephrosis (white arrow).

Intraoperatively, supraumbilical midline 2 cm vertical incision was given, a careful division of underlying structure performed up to parietal peritoneum, parietal peritoneum lifted up and divided to enter peritoneal cavity exercising care to avoid cyst wall injury, the cyst was punctured with 10mm trocar and cyst wall lifted upholding with two allis forceps. About 12.5 liters of fluid aspirated, a small portion of the cyst wall was sent for frozen section analysis (Fig. 2 A-D). The midline fascia was partially closed, a 10 mm cannula was introduced, pneumoperitoneum was created and the three additional working ports were placed (Fig. 3A). The whole of the peritoneal cavity was inspected, peritoneal fluid was collected for cytology; the cyst was seen arising from the right ovary; the contralateral ovary was apparently normal (Fig. 3B). Frozen section analysis reported epithelial tumor however malignancy could not be ruled out, so we proceeded with right-sided oophorectomy. Posterior peritoneum opened just below the infundibulopelvic ligament on the right side, right ureter identified, ovarian vessel coagulated and divided with the harmonic scalpel, fallopian tube divided and salpingo-oophorectomy completed. The cyst was removed through the supraumbilical vertical incision (Fig. 3C); thorough peritoneal irrigation and suction were

done with warm Ringer's lactate, the peritoneal biopsy was taken from the pelvis, paracolic gutter, and the pouch of Douglas.

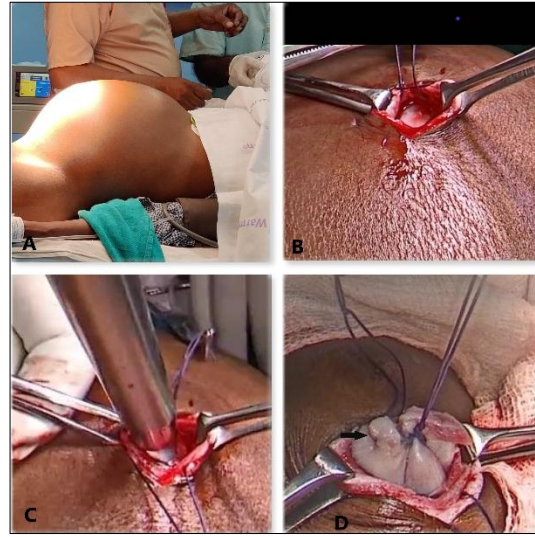


Figure 2: A) Patient on the operating table. B) Supraumbilical vertical incision on abdomen with cyst visible inside. C) 10 mm trocar is being introduced to cyst for drainage. D) Cyst wall stoma closed with a purse-string suture.

The patient made a good recovery and was discharged on the second postoperative day. Histopathology reported mature cystic teratoma of the ovary. She had been under regular follow-up for the last three months and was completely symptom-free.

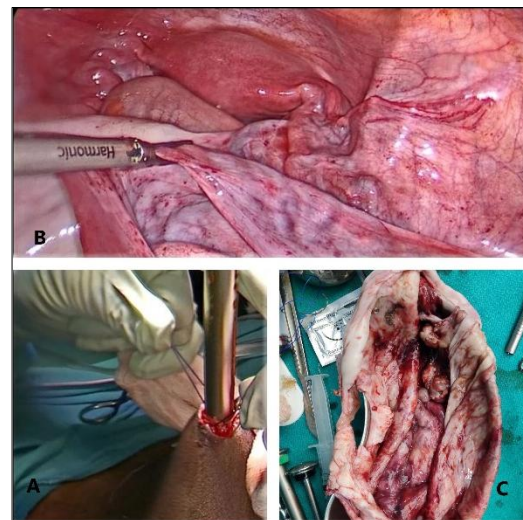


Figure 3: A) Rectus fascia closed partially and lifted up to introduce primary trocar and create pneumoperitoneum. B) Cyst arising from right ovary. C) Exteriorized cyst cut open.

## DISCUSSION

Traditionally, ovarian cysts >15 cm size are labeled as giant ovarian cysts, however, the designation should relate the size of the tumor with the size of the peritoneal

cavity among these young women. [4] Diagnosis of ovarian cystic teratoma is usually made on the basis of characteristic appearance on ultrasound (echogenic sebaceous material and calcification) or CT scans (fat attenuation within a cyst). [5] Large dermoid cysts are managed with surgical excision via laparotomy or laparoscopy. The minimally invasive technique has many advantages like a shorter hospital stay, minimal blood loss, better visibility, quick recovery, and improved cosmetic results, however major concern is the spillage of sebaceous content leading to chemical peritonitis. Shawki et al had reported only 0.2% incidence of chemical peritonitis after dermoid cyst excision and suggested that thorough irrigation of the peritoneal cavity reduced the risk of chemical peritonitis.[6] Only a few cases of giant dermoid cyst extending above the umbilicus and managed with laparoscopic excision are reported in the literature.[7,8] Pre-laparoscopy decompression of the cyst is essential to provide adequate working space, ease manipulation of the cyst, and avoid accidental perforation and spillage. All reported techniques of decompression include ultrasound-guided percutaneous drainage of the cyst [9] and mini-laparotomy drainage. [4] Whatever technique is resorted upon, inadvertent perforation and spillage should be avoided. Though the risk of malignancy is very low, the premonition of malignancy based on clinic-radiological features and inspection should preclude the laparoscopic approach.

## REFERENCES

1. Khanna S, Srivastava V, Saroj S, Mishra SP, Gupta SK. An unusual presentation of ovarian teratoma: a case report. *Case Rep Emerg Med.* 2012; 2012:1–2.
2. B. Caspi, Z. Appelman, D. Rabinerson, Y. Zalel, T. Tulandi, Z. Shoham. The growth pattern of ovarian dermoid cysts: a prospective study in premenopausal and postmenopausal women. *Fertil. Steril.* 1997; 68: 501-505
3. Abbas A, Gamal E, Talaat E, Sheha A. Torsion of huge dermoid cyst in adolescent girl: a case report. *Middle East Fertility Society Journal.* 2017; 22:236–239.
4. Dolan MS, Boulanger SC, Salameh JR. Laparoscopic management of giant ovarian cyst. *JLSLS.* 2006; 10:254–256.
5. Sahin H, Abdullazade S, Sancı M. Mature cystic teratoma of the ovary: a cutting edge overview on imaging features. *Insights Imaging.* 2017; 8(2):227-241. doi:10.1007/s13244-016-0539-9
6. Shawki, O., Ramadan, A., Askalany, A. Bahnassiet, A. Laparoscopic management of ovarian dermoid cysts: potential fear of dermoid spill, myths and facts. *Gynecol Surg* 4, 255–260 (2007).
7. Ye LY, Wang JJ, Liu DR, Ding GP, Cao LP. Management of giant ovarian teratoma: A case series and review of the literature. *Oncol Lett.* 2012; 4(4):672-676. doi:10.3892/ol.2012.793
8. Uyanıkoğlu H, Dusak A. A Huge Ovarian Dermoid Cyst: Successful Laparoscopic Total Excision. *J Clin Diagn Res.* 2017; 11(8):QD03-QD05. doi:10.7860/JCDR/2017/29262.10436
9. Cevrioglu AS, Polat C, Fenkci V, Yilmazer M, Yilmaz S, Dilek ON. Laparoscopic management following ultrasonographic-guided drainage in a patient with giant paraovarian cyst. *Surg Endosc.* 2004; 18(2):346. doi:10.1007/s00464-003-4226-9

**Conflict of Interest:** Nil

**Source of Support:** Nil

**Consent to Publication:** Author(s) declared taking informed written consent for the publication of clinical photographs /material (if any used), from the legal guardian of the patient with an understanding that every effort will be made to conceal the identity of the patient, however it cannot be guaranteed.

**Authors Contribution:** Author(s) declared to fulfill authorship criteria as devised by ICMJE and approved the final version. Authorship declaration form, submitted by the author(s), is available with the editorial office.

**Acknowledgements:** None