

Original Article

Foreign body ingestion and inhalation in pediatric age: Our experience at a tertiary care hospital

Khawar Abbas,*¹ Aftab Ali,¹ Muhammad Rashid,¹ Nadeem Akhtar,² Ali Raza,¹ Inayat ur Rehman¹

¹ Resident Pediatric Surgery Children Hospital, PIMS, Shaheed Zulfiqar Ali Bhutto Medical University, Islamabad

² Professor of Pediatric Surgery Children Hospital, PIMS, Shaheed Zulfiqar Ali Bhutto Medical University, Islamabad

Cite as: Abbas K, Ali A, Rashid M, Akhtar N, Rehman IU. Foreign body ingestion and inhalation in pediatric age: Our experience at a tertiary care hospital. J Pediatr Adolesc Surg. 2021; 2: Ahead.

This is an open-access article distributed under the terms of the Creative Commons Attribution License, which permits unrestricted use, distribution, and reproduction in any medium, provided the original work is properly cited (<https://creativecommons.org/licenses/by/4.0/>).

ABSTRACT

Background: Foreign bodies in aero digestive tract is a common emergency in pediatric age group.

Methods: This cross-sectional study included 156 patients of foreign bodies in aero digestive tract over a period of 2 years from January 2016 to December 2017.

Results: Out of 156 patients, foreign body in esophagus was found in 111 patients with age range from 6 months to 12 years. Fifty-six patients (50%) belonged to 3-5 years age group. Coin was found in most of the patients which constitutes 61(55%) patients. Majority of the foreign bodies got impacted in cricopharynx. Of all the patients, 45 had foreign body in airway with age ranging from 6 months to 12 years. Peanuts were found in majority of cases, constituting 20% and right bronchus was mostly affected. One patient of foreign body ingestion expired.

Conclusion: Early detection and referral to a well-equipped center can prevent mortality and morbidity.

Keywords: Aero digestive tract; foreign body; Esophagoscopy; Ingestion; inhalation.

INTRODUCTION

Foreign bodies in children is one of the major pediatric surgical emergency. Foreign bodies in aero digestive tract, if not diagnosed and managed early, can have serious consequences in terms of morbidity and mortality. Due to inquisitive nature, children are prone to foreign bodies, which at times can get stuck in esophagus and airway, resulting in fatality. Other reason for foreign body in aero digestive tract is that children explore object by mouthing and they cannot differentiate between edible and non-edible objects. Moreover, in young children there is immature swallowing coordination, inability to chew properly, absence of teeth and rapid breathing, all resulting in higher risks of aspiration [1].

Foreign body ingestion and inhalation are most common in preschool children. For an accurate diagnosis, a comprehensive history, detailed clinical examination and appropriate radiological investigations are important.

Antero-posterior (AP) and lateral chest X-ray or AP and lateral soft tissue neck radiograph are recommended if foreign bodies are suspected in aero digestive tract. Coin and button battery can be distinguished easily on radiograph as button battery has distinct double contour [2].

Consequences of ingested or inhaled foreign bodies depend on its size, shape, and anatomical location in aero digestive tract as well as patient's age and gender. Foltran F et al [3] concluded that in infants, inhaled/aspirated foreign body causing mechanical obstruction of airway is a major cause of fatal accidents and it represents a major cause of mortality in preschool children (about 7%).

The objective of this study was to present foreign body ingestion and inhalation cases observed in The Children's hospital, PIMS, Islamabad and to highlight the measures that should be taken to prevent foreign bodies.

METHODS

This cross-sectional study included 156 patients of foreign bodies in aero-digestive tract of children who presented to the Children hospital, PIMS, Islamabad from January 2016 to December 2017. Patients were enrolled from outpatient and emergency department according to inclusion and exclusion criteria. Those patients were included in this study who had age range from 6 months up to 12 years and referred from other hospitals. The patients already undergoing removal attempt in another hospital were excluded from the study. After thorough history and clinical examination, x ray neck and chest (antero-posterior and lateral view) were done to know the exact location of foreign body and establish the diagnosis. In those cases with no evidence of foreign body in neck and chest, x ray abdomen and pelvis was done. Having established the diagnosis, informed consent was taken from the parents. After pre-anesthesia assessment, patients were moved to the operating room for the procedure under general anesthesia. For critical patients especially of foreign body inhalation, Pediatric ICU bed was arranged pre-operatively and for post-operative care as well. Rigid bronchoscopy was done in cases of foreign body inhalation/aspiration. Foreign bodies in esophagus were removed by either magill forceps or with the help of rigid esophagoscopy. Patients were kept NPO for 3 hours after surgery. All patients of foreign body ingestion were discharged on the same day and all patients of foreign body inhalation after 24 hours after repeating chest X ray to rule out any post-operative complication like pneumothorax. All patients were followed after one week of surgery.

Following variables were observed in this study; age distribution, sex distribution, radiological findings, signs and symptoms, type of foreign body, location, time of presentation, treatment options and complications.

Data was analyzed using Statistical Software Package for Social Sciences (SPSS) version 21.

RESULTS

Among 156 patients, 90 were male and 66 were female. Foreign bodies in digestive tract were found in 111 (71.1%) patients and in airway in 45 (28.8 %) patients.

In airway and digestive tract, male were more affected than females, 63 (56.75%) and 27 (60%) cases respectively with M: F ratio of 1.3:1. Mean age of the patients was 3.36 ± 2.14 years.

Majority of patients having foreign body in digestive tract as well as respiratory tract belonged to age group 3-5years, 56 (50.45%) and 24(53.3 %) patients respectively [Fig:1].

Duration of foreign body ingestion ranged from 1 hour to 1 month. Eighty six (77.47 %) cases reported within first

6 hours, 19 (17.11%) cases within 6-24 hours, 6 (5.40%) after 24 hours. Duration of foreign body inhalation ranged from 1 hour to 2 months. Nineteen (42.22%) cases reported within first 6 hours, 15 (33.33 %) cases within 6-24hours, 6 (13.33%) within 1-3 days, 3 (6.66%) cases within 3 day to 1 month and 2 (4.44%) cases presented within 1-2 months.

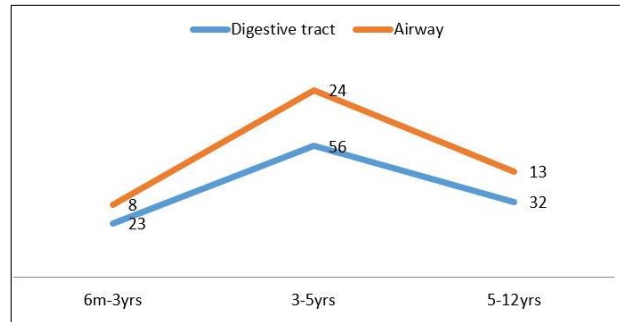


Figure 1: Age Distribution

The occurrence of signs and symptoms were dysphagia 53 (47.74%), odynophagia 27 (24.32%), foreign body sensation 17 (15.31 %) and vomiting 14 (12.61%) in patients with foreign body in digestive tract. While in airway tract the occurrence of symptoms were; rhonchi on auscultation in 23 (51.11%) and dyspnea in 12 (26.66%), decreased air entry in 7 (15.55%) and hyper resonance in 3 (6.66%) cases.

The most common foreign body ingestion was coin, in 61 patients (54.95%) and most common foreign body inhalation was peanut, in 9 patients (20%); while foreign body which was least common in digestive tract was vegetative foreign body found in 2 patients (1.8%) and in respiratory tract was safety pin found in 1 patient (2.22%) [Table 1].

Table 1: Type of Foreign Body and Distribution

S #.	Type	Digestive tract		Airway	
		Number	%	Number	%
1.	Coin	61	55	8	18
2.	Button battery	25	23	2	4
3.	Vegetative foreign body	2	2	3	7
4.	Safety pin	7	6	1	2
5.	Peanuts	0	0	9	20
6.	Betel nut	0	0	8	18
7.	Others	16	14	14	31

Only one patient of foreign body ingestion was expired. The patient was having button battery ingestion, presented after one week of ingestion, had esophago-aortic fistula. Before going for the procedure, the patient had hematemesis and expired on the same day of admission.

Cricopharynx had majority of foreign body in digestive tract, followed by hypopharynx and oropharynx. Two patients (1.8%) had foreign body in oropharynx which was removed by Magill forceps. Eighty-two patients (73.87%) had foreign body in cricopharynx, while 27 patients (24.32%) had foreign body in hypopharynx which were removed by direct laryngoscopy and rigid esophagoscopy and forceps removal.

Majority of the foreign bodies in airway tract was found in right bronchus, 33 (73.33%) followed by trachea 8 (17.78%) and left bronchus 4 (8.89%) which were removed by rigid bronchoscopy and forceps removal.

DISCUSSION

In a period of 2 years, 156 foreign bodies presented to our hospital and it can signify its importance and prevalence. Of the total, 111 patients had foreign body in digestive tract and 45 patients in respiratory tract.

Symptoms in cases of foreign bodies in esophagus depend on type and location of foreign body. Children may present with vomiting, dysphagia, drooling, dysphonia and irritability. Fever and gagging may be additional symptoms. Buttazzoni E et al. analyzed the symptoms associated with ingestion of button battery. They found dysphagia was the most common symptoms occurring in 30% of cases followed by cough and fever. They further analyzed the symptoms according to age and found that children younger than one year had irritability, anorexia, dysphonia and melena as a common symptom. Common symptoms in toddlers were dyspnea, fever, cough, drooling and vomiting while in children older than 5 years, thoracic and abdominal pain were common symptoms [1]. Dysphagia was the most common symptom in cases of foreign body ingestion in our study as well. Ingested foreign body, if passes easily through esophagus, has high chances that it will navigate through whole of gastrointestinal tract (GIT) without much difficulty. However, if it has irregular shape, it may get stuck anywhere in GIT causing mechanical obstruction. Perforation is a potential complication of foreign body ingestion. The common sites for perforation are esophagus, duodenum, appendix, ileocecal valve and recto sigmoid junction [4].

Foreign bodies in epiglottis or carina may cause respiratory failure. The most common symptom is 'penetration syndrome' in which there is acute onset of choking and intractable cough along with presence or absence of vomiting. Foreign bodies in supra glottis region may present with cough, breathing difficulty, salivation and voice change. Laryngeal foreign bodies may cause cough, stridor, severe dyspnea and changes in voice. If the foreign body is in extra thoracic trachea, inspiratory stridor and expiratory rhonchi are present while intra thoracic tracheal foreign bodies have inspiratory rhonchus and expiratory wheeze. When in bronchus, cough, wheeze, respiratory difficulty,

decreased breath sounds are present [4]. In our study rhonchi was the most common symptom after foreign body inhalation.

In case of suspected foreign body in airway, chest X-ray is usually done as first choice. Metallic foreign bodies are identified easily on radiographs. However, diagnosis is challenging in cases of radiolucent foreign bodies. Vegetable foreign bodies, for example, cannot be visualized on chest radiography unlike metallic foreign bodies. Radiolucent foreign bodies in airway can only be diagnosed by secondary changes on chest radiographs such as lung collapse, hyperinflation, hyperlucency by air trapping and chronic pulmonary changes [5]. Therefore, high index of suspicion is required in cases where children present with heterogeneous symptoms and vague history. Studies have shown normal X-ray finding in cases of foreign body inhalation in 9-35% of patients [6]. When standard inspiratory film is normal, an expiratory film may allow the visualization of trapped air by valve like effect in partial bronchial obstruction [7]. Sensitivity and specificity of chest X-ray in foreign body inhalation ranges from 60-85% and 52-68% respectively [8,9]. Bronchoscopy is required in cases where there is strong clinical suspicion of foreign body inhalation in the presence of negative chest X-ray. Bronchoscopy is highly sensitive and specific in diagnosis of foreign body inhalation and also serves as therapeutic tool. Behera et al evaluated the effectiveness of Multidetector computed tomography (MDCT) virtual bronchoscopy in diagnosing vegetative foreign body. They found that in patients with long standing respiratory symptoms without any obvious evidence, virtual bronchoscopy should be done in order to rule out vegetative foreign body [6]. Rigid bronchoscopy requires general anesthesia in pediatric patients and has complications such as laryngeal edema, pneumothorax, hypoxia, perforation and cardiopulmonary arrest. Complication rates of rigid bronchoscopy range from 2-22%, but these complications occur rarely in hands of experienced pediatric bronchoscopy teams [10-12]. In our study not a single patient had any bronchoscopy related complication.

Incidence of battery cell ingestion has increased dramatically over last few decades. Literature review shows only 6 cases reported till 1983, first being reported in 1977. Almost 66,000 patients younger than 18 years reported to US emergency Departments with button battery related injuries between 1990 and 2009, with average of 3289 battery-related Emergency Departments visits annually [13]. Factors related to this increase include increase in manufacturing of toys and devices incorporated with these kinds of batteries and shape of Battery cell mimicking candies that look attractive to children [1]. In our study Battery is second most common object after coins ingested by children. Consequences of button battery (BB) injury are drastic and are related to chemicals released from the button

battery, which can cause both tissue damage and systemic poisoning secondary to absorption of toxic substances released from BB. Most frequent mechanism of Battery injury described in literature is electrolytic current generation when battery comes in contact with tissue fluids resulting in production of hydroxide at battery's negative pole. This leads to serious complications such as necrosis resulting into perforation, fistula, hemorrhage and even death [1,14]. In our study, this happened to one patient of button battery ingestion who developed aorto-esophageal fistula and eventually death.

Characteristics and location of foreign bodies are important in development of signs and symptoms. Foreign bodies in aero digestive tract have wide range of symptoms. Small objects ingested pass easily through esophagus without any symptoms and if inhaled, may lodge deep down the air ways without producing symptoms. These foreign bodies go unnoticed for long and children are usually misdiagnosed and treated with antibiotics and bronchodilators for croup, asthma or pneumonia [15,16].

Out of total 156 patients, 111 patients had foreign body in digestive tract and 45 patients in respiratory tract. This is in concordance with a lot of other studies in which foreign body is more common in digestive tract [17-21]. In our study male were more affected with M: F ratio of 1.3:1 which is similar to other studies [22-24]. In literature the most common age group who are most affected is 3 years and below [22,25,26] but in our study, 3-5 years age group was most affected (50% in digestive and 53% in respiratory system).

Time of presentation is very important as earlier presentation is associated with low morbidity. In our study, majority of our patients with foreign body in aero digestive tract presented within first 24 hours just like in many other series [27,28]. Parents are very concerned about their children and foreign body creates a panic among them so they rush to hospital. Delayed presentation is mostly due to un-noticed foreign bodies and in asymptomatic patients.

In our study coin was the most common foreign body in digestive tract and peanut in respiratory tract, reason being ready availability of these objects. This is in agreement with other studies in which they found coin in majority of cases in digestive tract [27,28]. Our results showed that the most common site of lodgment of

foreign body in digestive tract is cricopharynx. The same is reported by different studies [27,28]. In many studies, right bronchus is the main site of lodgment of foreign bodies in respiratory tract [29, 30]. Similarly in our study, 73% patients had foreign body in right bronchus, reason it being anatomically vertical and broad.

In order to reduce morbidity, early recognition and management is mandatory. Prevention is important in order to reduce healthcare and social costs. Awareness programs regarding prevention of foreign body should be arranged for parents, teachers, babysitters and general public. Manufacturing of child-proof electronic appliances by industries is another way to prevent these fatal accidents. There is a need to develop algorithms for risk stratification so that prompt surgical intervention can be carried out in high risk cases. Surveillance Registries can be set up in order to prevent incidences of foreign body by studying the characteristics of foreign body, its presentation and complication [31,32]. These registries can help us in devising ways to prevent fatal accidents by foreign body inhalation and ingestion.

This study has certain limitations. It should be conducted on much bigger scale and long term follow up should be included.

CONCLUSION

Foreign body in aero-digestive tract is most common in children under 5 years of age. Rigid endoscopies (esophagoscopy and bronchoscopy) with forceps removal under general anesthesia is the best method of treatment. It is highly recommended that experienced Pediatric Surgeons/ENT surgeons should remove foreign bodies in aero-digestive tract. Since it can be preventive, so necessary measures should be taken accordingly by the parents.

Conflict of Interest: Nil

Source of Support: Nil

Consent to Publication: The authors declared taking consent for publication from legal guardians of the patient. Signed consent form has been submitted to the journal office.

Authors Contribution: Author(s) declared to fulfill authorship criteria as devised by ICMJE and approved the final version. Authorship declaration form, submitted by the author(s), is available with the editorial office.

Acknowledgements: The authors would like to thank their colleagues, Dr Sara, Dr Awais, Dr Amir for their help in literature review.

REFERENCES

1. Buttazzoni E, Gregori D, Paoli B, Soriani N, Baldas S, Rodriguez H, et al. Symptoms associated with button batteries injuries in children: An epidemiological review. *Int J Pediatr Otorhinolaryngol.* 2015; 79(12):2200-7.
2. Elloy MD, Worley GA, Bailey CM. Foreign body inhalation: a case of mistaken identity? *J Emerg Med.* 2010; 38(4):499-501.
3. Foltran F, Passali FM, Berchiolla P, Gregori D, Pitkaranta A, Slapak I, et al. Toys in the upper aerodigestive tract: new evidence on their risk as

- emerging from the Susy Safe Study. *Int J Pediatr Otorhinolaryngol.* 2012; 76 Suppl 1:S61-6.
4. Grassi R, Faggian A, Somma F, De Cecco CN, Laghi A, Caseiro-Alves F. Application of imaging guidelines in patients with foreign body ingestion or inhalation: literature review. *Semin Ultrasound CT MR.* 2015; 36(1):48-56.
 5. Zissin R, Shapiro-Feinberg M, Rozenman J, Apter S, Smorjick J, Hertz M. CT findings of the chest in adults with aspirated foreign bodies. *Eur Radiol.* 2001; 11(4):606-11.
 6. Behera G, Tripathy N, Maru YK, Mundra RK, Gupta Y, Lodha M. Role of virtual bronchoscopy in children with a vegetable foreign body in the tracheobronchial tree. *J Laryngol Otol.* 2014; 128(12):1078-83.
 7. Girardi G, Contador AM, Castro-Rodríguez JA. Two new radiological findings to improve the diagnosis of bronchial foreign-body aspiration in children. *Pediatr Pulmonol.* 2004; 38(3):261-4.
 8. Kosucu P, Ahmetoglu A, Koramaz I, Orhan F, Özdemir Ou, Dinç H, et al. Low-dose MDCT and virtual bronchoscopy in pediatric patients with foreign body aspiration. *Am J Roentgenol.* 2004; 183(6):1771-7.
 9. Haliloglu M, Ciftci AO, Oto A, Gumus B, Tanyel FC, Senocak ME, et al. CT virtual bronchoscopy in the evaluation of children with suspected foreign body aspiration. *Eur J Radiol.* 2003; 48(2):188-92.
 10. Jung SY, Pae SY, Chung SM, Kim HS. Three-dimensional CT with virtual bronchoscopy: a useful modality for bronchial foreign bodies in pediatric patients. *Eur Arch Otorhinolaryngol.* 2012; 269(1):223-8.
 11. Pinto A, Scaglione M, Pinto F, Guidi G, Pepe M, Del Prato B, et al. Tracheobronchial aspiration of foreign bodies: current indications for emergency plain chest radiography. *Radiol Med.* 2006; 111(4):497-506.
 12. Ciftci AO, Bingöl-Koloğlu M, Şenocak ME, Tanyel FC, Büyükpamukçu N. Bronchoscopy for evaluation of foreign body aspiration in children. *J Pediatr Surg.* 2003; 38(8):1170-6.
 13. Sharpe SJ, Rochette LM, Smith GA. Pediatric battery-related emergency department visits in the United States, 1990-2009. *Pediatr.* 2012; 129(6):1111-7.
 14. Litovitz T, Whitaker N, Clark L, White NC, Marsolek M. Emerging battery-ingestion hazard: clinical implications. *Pediatr.* 2010; peds. 2009-3037.
 15. Kim IG, Brummitt WM, Humphrey A, et al. Foreign bodies in the airway: a review of 202 cases. *Laryngoscope.* 1973; 83:347-354.
 16. Brooks JW. Foreign bodies in the air and food passages. *Ann Surg.* 1972; 175(5):720-732.
 17. Japhet M Gilyoma, Phillip L Chalya. *BMC Ear Nose Throat Disord.* 2011; 11:2.
 18. Rothman BF, Boeckman CR. Foreign bodies in the larynx and tracheobronchial tree in children. A review of 225 cases. *Ann Otol, Rhinol laryngol.* 1980; 89:434-36.
 19. Escramado RM, Richardson MA. Laryngotracheal foreign bodies. *Am J. Dis Child.* 1980; 134(1):68-71.
 20. Blazer S, Naveh Y, Friedman A. Foreign bodies in the airway. *Am J Dis Child.* 1980; 34:68-71.
 21. Schmidt H, Manegold BC. Foreign body aspiration in children. *Surg Endosc.* 2000; 14(7):644-8.
 22. Khan NU, Nabi IU, Yousaf S. Foreign bodies in larynx and tracheobronchial tree. *Pak Armed Forces Med J.* 2000; 50(2):68-70.
 23. Mu L, He P, Sun D. Inhalation of foreign bodies in Chinese children: a review of 400 cases. *Laryngoscope.* 1991; 101(6):657-60.
 24. Tariq P. Foreign body aspiration in children. a persistent problem. *J. Pak Med Ass.* 1999; 49(2):33-6.
 25. Fernandez JI, Gutierrez SC, Alvarez MV. et al. Foreign body aspiration in childhood - A report of 210 cases. *Ann Esp Paediatr.* 2000; 53(4):335-38.
 26. Murty PSN, Vijendra S, Ramakrishna S. Foreign bodies in the upper aerodigestive tract. *SQU Journal for Scientific Research Medical Sciences.* 2001; 3(2):117-20.
 27. Uba AF, Adeyemo AO, Adejuyigbe O. Management of esophageal foreign in children. *East Afr Med J.* 2002; 79(6):334-8.
 28. Diaz GA, Valledo L, Seda F. Foreign bodies from the upper aerodigestive tract of children in Puerto Rico. *Bol Asoc Med PR.* 2000; 92(9-12):124-9.
 29. Schmidt H, Manegold BC. Foreign body aspiration in children. *Surg Endosc.* 2000; 14(7):644-8.
 30. Ullah A, Ullah I, Rasool G, Billah M. Endoscopic Removal of the tracheobronchial Foreign Bodies At a peripheral Hospital. *J Postgrad Med Inst [Internet].* 2011 Oct. 5 2022 Mar. 23; 18(3).
 31. Huang T, Li WQ, Xia ZF, Li J, Rao KC, Xu EM. Characteristics and outcome of impacted button batteries among young children less than 7 years of age in China: a retrospective analysis of 116 cases. *World J Pediatr.* 2018; 14(6):570-5.
 32. Pecorari G, Tavormina P, Riva G, Landolfo V, Raimondo L, Garzaro M. Ear, nose and throat foreign bodies: the experience of the Pediatric Hospital of Turin. *J Paediatr Child Health.* 2014; 50(12):978-84.