

## Case Report

# A newborn with anterolateral diaphragmatic defect: An unusual anomaly?

A. Mohamed,<sup>1</sup> S. Shankar,<sup>2</sup> A. Qazi,<sup>3</sup>

1 Specialist Surgeon, Aljalila Children Specialty Hospital, Dubai UAE

2 Consultant Neonatologist, Aljalila Children Specialty Hospital, Dubai UAE

3 Consultant Pediatric Surgeon, Aljalila Children Specialty Hospital, Dubai UAE

**Cite as:** Mohamed A, Shankar S, Qazi A. A newborn with anterolateral diaphragmatic defect: An unusual anomaly? J Pediatr Adolesc Surg. 2020; 1:114-116.

This is an open-access article distributed under the terms of the Creative Commons Attribution License, which permits unrestricted use, distribution, and reproduction in any medium, provided the original work is properly cited (<https://creativecommons.org/licenses/by/4.0/>).

## ABSTRACT

**Background:** Anterolateral defect of diaphragm is unusual and has been reported less than 5 times in literature.

**Case Presentation:** We are reporting a case with typical initial presentation of a congenital diaphragmatic hernia. A chest x-ray raised suspicion of a cystic lesion or diaphragmatic eventration which was excluded by chest ultrasound. At operation he was found to have a localized and large anterolateral defect with a very thick sac which was plicated to bridge the diaphragmatic defect.

**Conclusion:** A rare variant and should be differentiated from other variants using imaging.

**Keywords:** Congenital diaphragmatic hernia; Anterolateral defect; Diaphragmatic eventration.

## INTRODUCTION

Management of congenital diaphragmatic hernia (CDH) remains a challenge despite of major advancement in surgical treatment and neonatal critical care services and innovations like plug the lung until it grows (PLUG study)<sup>1</sup>. This is due to associated severe pulmonary hypoplasia of not only the ipsilateral lung but the opposite lung as well. Incidence of CDH is about 1 in 2000 live birth. One third of infants with CDH have still birth. Fifty percent will have associated congenital anomalies (cardiovascular anomalies, urogenital anomalies, musculoskeletal anomalies, central nervous system anomalies and non-rotation of gut). All these conditions together play significant role in prognosis and survival<sup>2</sup>.

There are three common defects in diaphragm: posterolateral (Bochdalek hernia) 90% of CDH and majority on left, Morgagni hernia and central hernia both account 10% of CDH<sup>2</sup>. We are reporting unusual case of anterolateral diaphragmatic defect.

## CASE REPORT

A full term male new born, antenatally diagnosed with left CDH was referred from another health facility. He was delivered via elective lower segment caesarean section. He was intubated and ventilated and required moderate ventilator settings to maintain adequate gas exchange. He also received Inotropes for hypotension. Echocardiogram showed moderately elevated pulmonary arterial pressures at 40 mm of Hg and it was managed by adequate cardiorespiratory support without the need of inhaled nitric oxide). Chest x-ray raised suspicion of left diaphragmatic eventration (Figure 1), hence ultrasound chest was done to confirm left CDH (left-sided diaphragmatic hernia with bowel loops in the left chest and partial extension of the left lobe of the liver and the stomach adjacent to the left border of the heart). By day three his ventilation was much improved without inotropes (Patient was on AC/PC mode ventilation setting, PCO<sub>2</sub> 38.5 – was 68.3 and PO<sub>2</sub> 49.2 – was 54.4). Surgery was performed on day 3 through left subcostal incision. Posteromedially the diaphragm was intact. The

defect was anterolateral containing a thick sac comprising almost 30% of the entire left diaphragm (Figure 2).

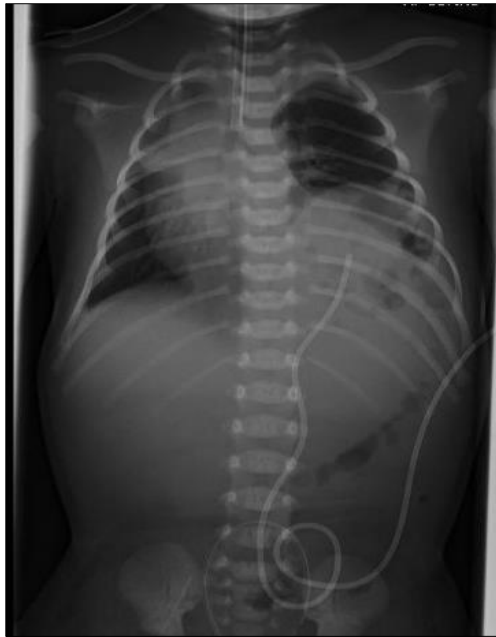

Figure 1: Chest x-ray before surgery

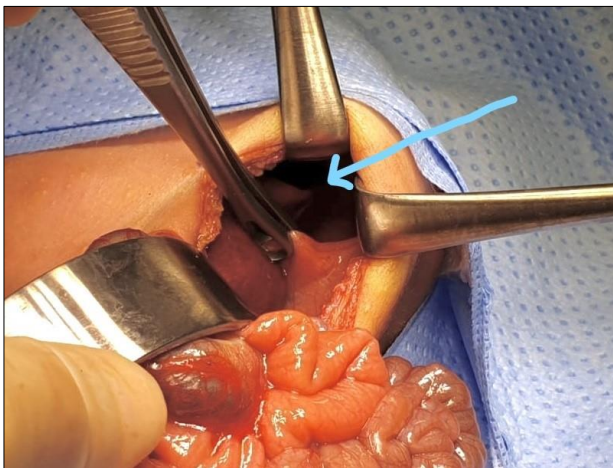


Figure 2: Intra-operative findings: arrow shows large anterolateral diaphragmatic defect.

The sac was thick enough to consider this as eventration localised to the anterolateral part. Posteromedial diaphragm had good muscle thickness. Stomach, left lobe of liver, spleen and most of the bowel was herniating up in the left chest. The small bowel was in normal rotation with duodenojejunal junction to the left of the spine. Lung was small volume in left hemi-thorax and inflating only minimally. Diaphragmatic defect was repaired by plicating the thick sac with multiple interrupted 3/0 prolene sutures. Post-operative period was uneventful. He was extubated on 5th postoperative day and was tolerating full feed (Picture 3). He was discharged home in good condition. In a post-operative

follow up after six weeks' patient is asymptomatic with no residual chest deformity. Newborn genetic screening result are normal.

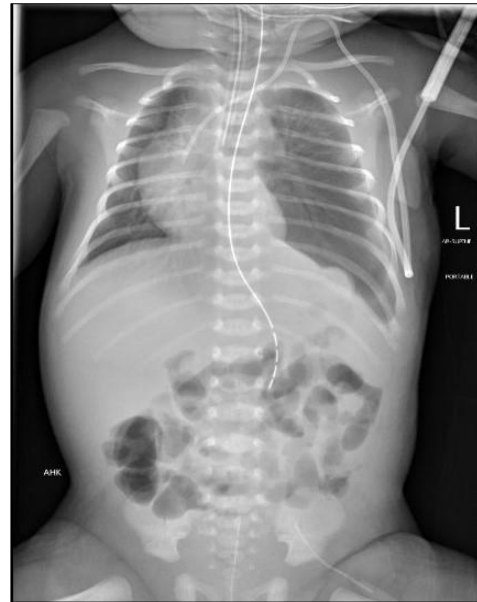

Figure 3: Chest x-ray 5 days after surgery.

## DISCUSSION

The Diaphragm starts to develop during in the fourth week of gestation, its fusion of four embryological components: septum transversum (anteriorly), pleuroperitoneal folds (dorsolateral), crura from the oesophageal mesentery (dorsally) and body wall of mesoderm (posteriorly). It begins to form anteriorly and migrates dorsally <sup>2</sup>.

The anterolateral diaphragmatic defect is unusual, which can be associated with congenital anomalies and has specific features. The defect is large located anteriorly and extends laterally to pars costalis, multiple intra-abdominal organs can herniate in this large defect and has lung hypoplasia which varies in severity as was seen in our patient<sup>2</sup>. The transabdominal approach with interrupted sutures was enough to closed the defect primarily without the need for synthetic patch. Due to the presence of thick sac, we were able to use it for plication and avoided the need for the patch.

There are three case report in European Journal of surgery in 1993 <sup>3</sup>. Two of the reported patients were 20 months of age, one presented with dyspnoea and other for elective ventral hernia repair, anterolateral defect was discovered intraoperatively. Both of them had associated intestinal malrotation which was corrected by and had uneventful postoperative course. Our patient did not have malrotation, which possibly suggests that the defect happened due to some incident after normal development of diaphragm. The third case was an infant

who died at 15 hours after surgery and autopsy showed left lung hypoplasia and left pulmonary artery with absent rectus abdominus<sup>3</sup>.

In conclusion, the anterolateral diaphragmatic defect is a rare anomaly that possibly occurs subsequent to the normal development of diaphragm. It may sometimes be associated with intestinal malrotation. It can also mimic eventration which can be distinguished with further imaging studies (e.g. ultrasounds)<sup>4</sup>.

**Conflict of Interest:** Nil

**Source of Support:** Nil

## REFERENCES

1. Hedrick M. H, Estes J. M, Sullivan K. M, et al. Plug the lung until it grows (PLUG): A new method to treat congenital diaphragmatic hernia in utero. *Journal of Pediatric Surgery*, Vol29, No 5(May)1994: pp 61Z -617
2. Tsao K, Lally K. P. Congenital diaphragmatic hernia and Eventration. In: George W. Holcomb III, J. Patrick Murphy, Daniel J Ostlie. *Ashcraft's Pediatric Surgery*. Elsevier saunders; 6th Edition 2014.pp. 315-316
3. Stener Z, Mares A.J, Anterolateral Diaphragmatic Hernia: Is it a Morgagni Hernia? *Eur J Pediatr Surg* 3 (1993) 112-114
4. Yazici M, et al. Congenital eventration of the diaphragm in children: 25 years' experience in three paediatric surgery centres. *Eur J Pediatr Surg* 2003 13: 298-301.

**Consent to Publication:** Author(s) declared taking informed written consent for the publication of clinical photographs/material (if any used), from the legal guardian of the patient with an understanding that every effort will be made to conceal the identity of the patient, however it cannot be guaranteed.

**Authors Contribution:** Author(s) declared to fulfill authorship criteria as devised by ICMJE and approved the final version. Authorship declaration form, submitted by the author(s), is available with the editorial office.

**Acknowledgements:** None