

Innovation & Technique

Automatic planning of paediatric craniofacial deformities: New virtual facial-symmetry operative detection

Giuditta Mannelli,^{1*} Antonio Marzola,² Francesco Buonamici,² Yari Volpe,² Francesca Uccheddu,² Giuseppe Spinelli,³

1 Head and Neck Oncology and Robotic Surgery, Department of Experimental and Clinical Medicine, University of Florence, Italy

2 Department of Industrial Engineering, University of Florence. Via Santa Marta 3, 50139, Florence, Italy

3 Department of Maxillo Facial Surgery, Azienda Ospedaliero-Universitaria Careggi, Largo Palagi 1, 50134, Florence, Italy

Cite as: Mannelli G, Marzola A, Buonamici F, Volpe Y, Uccheddu F, Spinelli G. Automatic planning of paediatric craniofacial deformities: new virtual facial-symmetry operative detection. J Pediatr Adolesc Surg. 2024; 2:57-60.

This is an open-access article distributed under the terms of the Creative Commons Attribution License, which permits unrestricted use, distribution, and reproduction in any medium, provided the original work is properly cited (<https://creativecommons.org/licenses/by/4.0/>).

ABSTRACT

Background: The correction of craniofacial deformities is an ongoing challenge in maxillofacial surgery. However, conventional measurement methods for treatment planning are not appropriate for craniofacial surgery. Computer-assisted approaches can improve surgical outcomes. A new, non-invasive, patient-specific automatic method, proposed here, has been tested for assisting the surgeon in preoperative planning.

Case Presentation: In the case reported, the described method allows effective surgery planning that led to a significant decrease in asymmetries in the orbital region.

Conclusion: The multidisciplinary collaborative approach is a central element for the construction of effective personalized procedures and for the conception of new surgical approaches. The here proposed technology offers a good level of feasibility and has an achievable potential for breakthroughs in the improvement of facial deformities surgical treatment, thus representing an overwhelmingly useful tool in a clinical setting.

Keywords: Craniofacial deformities, Virtual facial-symmetry, Surgical planning.

INTRODUCTION

Approximately one-third of all birth defects affect the craniofacial region. Surgery represents the only therapeutic option, and it provides complex and often multiple interventions, including long-hospital stay and risk for major postoperative complications. Since the craniofacial region is complex, a comprehensive understanding of the problem is the first step before carrying out the definitive reconstruction. [1-3]

At our Institution, we have increasingly used preoperative patient-specific 3D models to plan uncommon craniofacial operations. [4] In this setting, the introduction

of an automatic method to improve the accuracy and reliability of computer-aided technologies (CAx), enables the automation of patient-specific pre-operative planning for craniofacial skeleton surgery. The ambition of this project is to provide surgeons with new and valid technology capable of positively influencing preoperative surgical planning, its explanation, and the intra-operative management of pediatric patients.

CASE PRESENTATION

This study proposes a novel systematic procedure that embeds the cutting-edge algorithms of image and 3D processing towards the full automation of craniofacial

Correspondence*: Giuditta Mannelli, MD, Head and Neck and Robotic Surgery, Department of Experimental and Clinical Medicine, University of Florence, Largo Brambilla 3, 50134 Florence, Italy.

Email: mannelli.giuditta@gmail.com

Submitted on: 02-11-2020

© 2024, Mannelli et al.

Accepted on: 30-01-2021

dysmorphisms surgical treatment planning. The proposed approach is sketched in Figure 1.

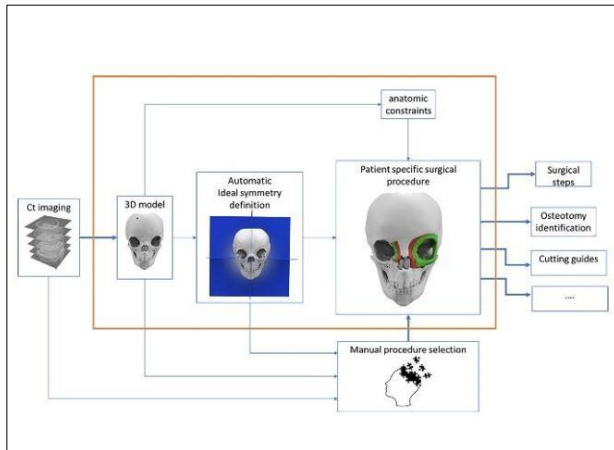


Figure 1:

The automation macroblocks are enclosed in the orange frame. The procedure input is represented by patient imaging (i.e., CT scan). The surgeon fine-tunes the proposed anatomical and physical constraints and chooses the surgical procedure. The output gives a patient-specific surgical procedure plan, conveying surgical steps and possibly the CAD models of the customized cutting guides for both simulation and physical surgery.

While the 3D model reconstruction from CT data usually embeds semi-automatic function for such a reconstruction [5], the automatic skull symmetry definition is an ongoing challenge. To automatically determine the three orthogonal anatomical planes needed for a 3D asymmetry evaluation are required: (i) an algorithm able to find the plane that best separates (along the sagittal direction) the skull into two almost equal and symmetric halves and (ii) a referred number of anatomical landmarks to define the equations of the remaining two anatomical planes (frontal and coronal ones), respectively. Once the planes are determined, the 3D facial symmetry analysis [6] is performed by comparing the 3D location of a set of further anatomical landmarks with their counterparts. The type and number of such landmarks depend on the specific dysmorphism and the interested facial region.

We applied this automatic virtual planning method to a pilot clinical case of a young 5-year-old female, affected by hiperteleorbitism. Parents gave their informed consent to let their child be enrolled in this study and to undergo the surgical procedure. She had a primary procedure of left orbital box medialization together with right medial canthopexy performed by a combined open surgical approach. Surgery simulation was preoperatively performed by using CT imaging (slice thickness of 1 mm); automatic thresholding and segmentation of her facial skeleton were carried on by

Mimics 21.0 [7], which enables the conversion of the DICOM images into STL 3D file format, and patient's MSP was detected and determined by applying the consolidated automatic algorithm.[8]

The facial transversal plane (i.e. Frankfurt Plane) was defined as the one passing through the left orbital point (Or) and the left and right porion (Po). The frontal plane was perpendicular to the axial and sagittal ones, and it passed through the left Po.

Table 1. Description and Abbreviation of the selected landmarks

Landmark	Abbreviation	Description
Supraorbital Foramen	SOF	The midpoint of supraorbital foramen
Frontozygomatic Suture	FZS	The most medical and anterior point of left frontozygomatic suture at the level of the lateral orbital rim
Ectoconchion	EC	The intersection of the most anterior surface (edge) of the lateral orbital border and a line parallel to the superior orbital border that bisects the orbit into two equal halves.
Orbital	OR	The lowermost pint in the lower margin of the bony orbit.
Fontorbitomaxillare	FOM	Lateral point of the frontomaxillary suture on the medical margin of the orbit.

In the reported case, landmarks specified in Table 1 were manually identified by clicking on the skull 3D model, to assess the skull asymmetry and to drive patient-specific surgical osteotomies. The preoperative skull measurements (reported in mm), were given as the distance of each landmark from the three planes of reference, and they are reported in Table 2.

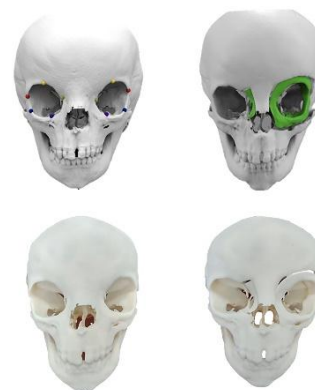

Figure 2:

According to such measurements, osteotomies and bone mobilization were evaluated by means of a Computer-Aided (CAD) procedure; the analysis of the symmetry of

the identified landmarks on the 3D model simulating the intervention (Table 2). The calculated mobilizations are related to the standard surgical approach chosen by the surgeon. The proposed CAD procedure provides the optimal outcome and related bone mobilization according to these constraints. A 3D printing of the skull before surgery, as well as the skull with the predefined cutting lines, was also delivered to the surgical team to enable a reliable simulation of the surgical procedure (Fig. 2).

Table 2. Pre-surgical osteotomy landmarks 3D distances and post-surgery landmarks distances; [R=right, L=left, RL=right to left, LMRKS=landmarks, SOF=supraorbital foramen; FZS=Fronto-zygomatic Suture; EC=Ecto-conchion; OR=orbital; FOM=Fronto-rbito-maxilla;]

		LMRKS				
		SOF	FZS	EC	OR	FOM
PRE-SURGERY MEASUREMENTS						
Mid-sagittal Plane	R	29.7	45.1	41.5	19.5	12.2
	L	29.4	46.3	43.8	23.7	15.9
	R-L	0.3	-1.1	-2.3	-4.2	-3.7
Frankfurt Plane	R	32.0	18.7	7.2	2.6	18.5
	L	33.8	25.8	8.9	4.3	17.4
	R-L	-1.8	-7.1	-1.7	-1.7	1.1
Frontal Plane	R	56.9	39.7	41.8	56.7	59.4
	L	55.9	36.0	38.3	53.7	55.7
	R-L	1.0	3.7	3.5	3.0	3.7
POST-SIMULATION MEASUREMENTS						
Mid-sagittal Plane	R	29.7	45.1	41.5	19.5	8.2
	L	24.9	42.9	39.3	18.5	11.0
	R-L	4.8	2.2	2.2	1	-2.8
Frankfurt Plane	R	32.0	18.7	7.2	2.6	18.5
	L	32.1	23.2	6.7	2.7	15.6
	R-L	-0.1	-4.5	0.5	-0.1	2.9
Frontal Plane	R	56.9	39.7	41.8	56.7	59.4
	L	59.0	40.4	42.7	56.6	57.5
	R-L	-2.1	-0.7	-0.9	0.1	1.9

DISCUSSION

Personalized approaches in medicine prove to increase benefits and reduce risks for patients, improving both the safety and efficacy of medical processes and

REFERENCES

- Hong CJ, Giannopoulos AA, Hong BY, Witterick IJ, Irish JC, Lee J, et al. Clinical applications of three-dimensional printing in otolaryngology-head and neck surgery: a systematic review. *Laryngoscope*. 2019;129:2045-52.
- Hsieh TY, Dedhia R, Cervenka B, Tollefson TT. 3D printing: current use in facial plastic and reconstructive surgery. *Curr Opin Otolaryngol Head Neck Surg*. 2017;25:291-9.
- Marzola A, Governi L, Genitori L, Mussa F, Volpe Y, Furferi R. A semi-automatic hybrid approach for

products. [9,10] Our model showed the advantage of using an automatic tool for the surgery simulation both virtual and physical (i.e. 3D-printed replicas of real skulls) allowing the identification of pitfalls specific to hiperteleorbitism. The frontal-orbital approach was performed on the 3D virtual model and allowed the perception of the experience of the orbit and cranial base cuts. In addition, the exposed bone anatomy, without any tissue above or below, is a unique opportunity to the training surgeon. Barrel staves osteotomies were performed in the scaphocephaly model, and the bone was bent resembling the native bone. The quantitative results of our simulation were provided by both analyzing the symmetry of certain anatomic points (i.e. the left and right FOM points) and by leveraging a global asymmetry measurement (the asymmetry value index, AVI) provided by the algorithm that automatically evaluates the MSP. [8] The presented case reported a value of 1.23 mm AVI in the pre-surgical 3D model, 1.10 mm AVI in the simulation post-operative, and 1.19 mm in the real post-operative. This result shows a considerable decrease of the asymmetry between pre- and post-surgery, with a pre-operative and planned post-operative inter-orbital distance (IOD) of 28.5mm and 19.9mm respectively, and a final result of IOD of 19.7mm.

In conclusion, such strategies, if translated from single isolated cases and introduced into clinical practice, could lead to a profound and radical modification of the world of health care; in our opinion, it allows for a virtual run-through of different scenarios to arrive at the best overall treatment choice.

Conflict of Interest: Nil

Source of Support: Nil

Acknowledgements: We thank the Pediatric Radiology Unit for the acquisition of DICOM images, while the Computer-Aided procedures, as well as, the 3D preoperative models were performed by the Department of Industrial Engineering. The Surgical team cared for the MIMICS operations and to speak preoperatively with the young patients' families.

Consent to Publication: Author(s) declared taking informed written consent for the publication of clinical photographs /material (if any used), from the legal guardian of the patient with an understanding that every effort will be made to conceal the identity of the patient, however it cannot be guaranteed.

Authors Contribution: Author(s) declared to fulfill authorship criteria as devised by ICMJE and approved the final version. Authorship declaration form, submitted by the author(s), is available with the editorial office.

- defective skull reconstruction. *Comput Aided Des Appl.* 2019;17:190-204.
4. Di Angelo L, Di Stefano P, Governi L, Marzola A, Volpe Y. A robust and automatic method for the best symmetry plane detection of craniofacial skeletons. *Symmetry.* 2019;11:245-58.
 5. Carfagni M, Facchini F, Furferi R, Ghionzoli M, Governi L, Messineo A, et al. Towards a CAD-based automatic procedure for patient-specific cutting guides to assist sternal osteotomies in pectus arcuatum surgical correction. *J Comput Des Eng.* 2019;6:118-27.
 6. Gupta A, Kharbanda OP, Sardana V, Balachandran R, Sardana HK. A knowledge-based algorithm for automatic detection of cephalometric landmarks on CBCT images. *Int J Comput Assist Radiol Surg.* 2015;10:1737-52.
 7. Volpe Y, Furferi R, Governi L, Uccheddu F, Carfagni M, Mussa F, et al. Surgery of complex craniofacial defects: a single-step AM-based methodology. *Comput Methods Programs Biomed.* 2019;165:225-33.
 8. Jacobs CA, Lin AY. A new classification of three-dimensional printing technologies: systematic review of three-dimensional printing for patient-specific craniomaxillofacial surgery. *Plast Reconstr Surg.* 2017;139:1211-20.
 9. Dzau VJ, Ginsburg GS, Van Nuys K, Agus D, Goldman D. Aligning incentives to fulfill the promise of personalized medicine. *Lancet.* 2015;385:2118-9.
 10. Forte AJ, Alonso N, Persing JA, Pfaff MJ, Brooks ED, Steinbacher DM. Analysis of midface retrusion in Crouzon and Apert syndromes. *Plast Reconstr Surg.* 2014;134:285-93.