

Case Report

Spontaneous enterocutaneous fistula in an infant: A case report

Gali Divya,* Pinaki R Debnath, Vijay Kumar Kundal, Anil Kumar, Arnab Kumar, Amita Sen

Department of Pediatric Surgery, Atal Bihari Vajpayee Institute of Medical Sciences & Dr. Ram Manohar Lohia Hospital, New Delhi- 110001, India

Cite as: Diyya G, Debnath PR, Kundal VK, Kumar A, Kumar A, Sen A. Spontaneous enterocutaneous fistula in an infant. J Pediatr Adolesc Surg. 2024; 2:41-43.

This is an open-access article distributed under the terms of the Creative Commons Attribution License, which permits unrestricted use, distribution, and reproduction in any medium, provided the original work is properly cited (<https://creativecommons.org/licenses/by/4.0/>).

ABSTRACT

Background: Enterocutaneous fistulae (ECF) most commonly occurs following intestinal surgery. Spontaneous ECF is a rare entity in infants. Early presentation to the hospital decreases complication.

Case Presentation: A 2.5-month-old infant developed spontaneous ECF below the umbilicus following abdominal wall erythema and abdominal wall abscess. The bowel mucosa prolapsed out on straining efforts. Work-up was uneventful. At operation, the fistula was mobilized, and intestinal continuity was restored. Postoperative recovery was uneventful.

Conclusion: Spontaneous development of ECF is a rare entity in children. Every effort should be made to identify the etiology before labeling it as spontaneous.

Keywords: Enterocutaneous fistula, Necrotizing fasciitis, Primary closure.

INTRODUCTION

Enterocutaneous fistulae (ECF) in children are usually followed by intestinal surgery or inadvertent incision over an inflamed bowel adherent to the skin, mimicking an abscess.[1] But spontaneous enterocutaneous fistula over the abdominal wall without any prior intervention is very rare. We found no such reported case in the literature. Herein, we are reporting a rare case of spontaneous ECF over the abdominal wall with a prolapsed small bowel loop.

CASE REPORT

A two-and-a-half-month-old female child was brought to the pediatric surgical emergency with feculent discharge from a wound below the level of the umbilicus. The baby was full-term, born by normal vaginal delivery in an institute, with the mother having gestational diabetes, and there are no antenatal events. At the time of presentation, the child was clinically stable, tolerating oral feeds, and passing stools normally. The mother gave a history of abdominal wall erythema below the umbilicus 20 days before presentation to the hospital,

over which mother applied turmeric and oil; and she consulted a local practitioner, who prescribed antibiotics for the same. Subsequently, the child developed an abscess which ruptured spontaneously following which the child developed feculent discharge from the wound with a small visible mass that seems like bowel mucosa (Fig.1A). X-ray abdomen was normal and ultrasound confirmed the mass as bowel mucosa. When the child cried excessively, the bowel loop prolapsed through the wound (Fig.1B). The patient was taken for surgery and exploration was done by giving incision at the fistula site. Prolapsed bowel loop reduced and fistula site over the small loop identified on the antimesenteric border, approximately 50 cm proximal to the ileocecal junction. Margins of the fistula site on the bowel wall were sent for biopsy, edges freshened, and intestinal continuity established by closing the two ends with 4-0 Vicryl in a single layer (Fig.1C, 1D). The postoperative period was uneventful, and the child was allowed oral feed on the 4th postoperative day when the child started passing stool and discharged from the hospital on the 8th postoperative day. Histopathology showed normal bowel mucosa, no features of inflammatory bowel disease. On a

6-month follow-up, the child was symptom-free, gaining weight with normal developmental milestones as per age.

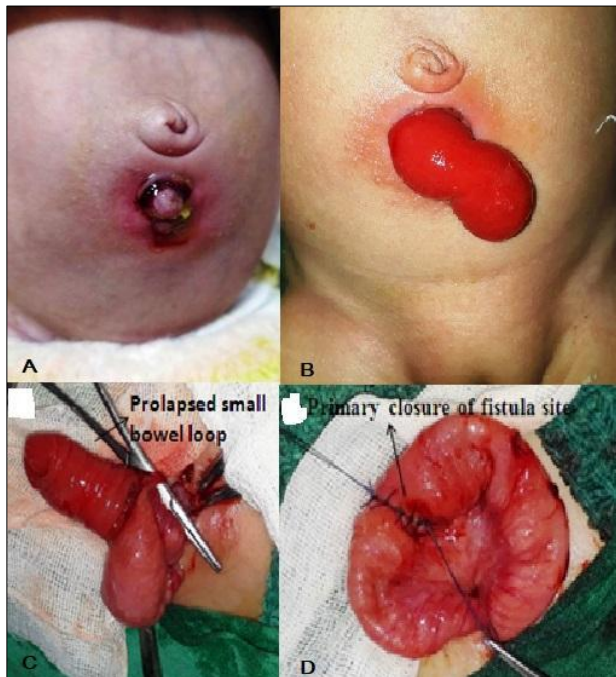


Figure 1: A) Showing wound below umbilicus with feculent discharge. B) prolapsed mucosa of small bowel through the ECF site. C) Mobilized ECF. D) Primary closure of the ECF

DISCUSSION

Enterocutaneous fistula can occur as a postoperative complication, following trauma, or spontaneously. Spontaneous ECF is very rare, especially over the abdominal wall. More than 75% of ECF are seen after surgery and 15- 25% are seen after abdominal trauma or spontaneously. Spontaneous ECF is observed in cases of necrotizing enterocolitis, inflammatory bowel disease, after radiotherapy, and malignancy.[2] The ileum is the most common site for the development of ECF.[3]

Approximately 10 cases of spontaneous scrotal ECF in case of incarcerated inguinal hernia were reported in infants.[4] Few patients had necrotizing fasciitis of the scrotum among them. There are case reports of Richter's hernia presenting as spontaneous enterocutaneous fistula in adults.[5-7] In the majority of these cases, primary anastomosis of the bowel was done as in our case because there was not any peritoneal contamination.

REFERENCES

1. Campos AC, Andrade DF, Campos GM, Matias JE, Coelho JC. A multivariate model to determine prognostic factors in gastrointestinal fistulas. *J Am Coll Surg.* 1999;188(5):483-90.
2. Berry SM, Fischer JE. Classification and pathophysiology of enterocutaneous fistulas. *Surg Clin North Am.* 1996;76(5):1009-18.
3. Kumar P, Maraju NK, Kate V. Enterocutaneous fistulae: etiology, treatment, and outcome - a study from South India. *Saudi J Gastroenterol.* 2011;17(6):391-5.
4. Raj P, Birua H, Prasad VK. Enteroscrotal fistula in a neonate following incarcerated inguinal hernia. *J Neonat Surg.* 2017;6:71.

Early presentation decreases the complications like exco-riation of surrounding skin and subsequent necrotizing fasciitis and post-operative wound infection. If there is bowel prolapse, as in our case, early surgery helps in preserving the bowel, because delay in surgery may cause ischemia and gangrene of the bowel, sometimes requiring entero-stoma.

ECF can be managed conservatively or surgically. Post-operative ECF with no distal obstruction can be managed expectantly as there is a chance of spontaneous closure with proper enteral and Total Parenteral Nutrition (TPN), especially in high-risk cases. But the majority of spontaneous ECF required surgical intervention. Spontaneous closure is rare in spontaneous ECF because of the presence of inflammation. Mucosal prolapse is also one of the hindering factors for spontaneous closure as found in our case. The majority of the reported cases underwent surgical intervention.[4,8,9] None of the cases in the study of Amjad et al. healed spontaneously.[8] Karabulut et al. concluded in their study that octreotide acts as an adjunctive agent in conservative management of ECF, and it further reduces the risk of sepsis and hospital stay.[10]

In conclusion, spontaneous ECF in infants does exist. Early presentation to the hospital decreases complications like ammoniacal dermatitis of the surrounding skin and may not progress to necrotizing fasciitis. Spontaneous closure is rare in cases of spontaneous ECF requiring early surgery. Most of the cases do not have peritoneal contamination, hence primary anastomosis is possible with a good postoperative outcome

Conflict of Interest: Nil

Source of Support: Nil

Consent to Publication: Author(s) declared taking informed written consent for the publication of clinical photographs /material (if any used), from the legal guardian of the patient with an understanding that every effort will be made to conceal the identity of the patient, however it cannot be guaranteed.

Authors Contribution: Author(s) declared to fulfill authorship criteria as devised by ICMJE and approved the final version. Authorship declaration form, submitted by the author(s), is available with the editorial office.

Acknowledgements: None

5. Ahi KS, Moudgil A, Aggarwal K, Sharma C, Singh K. A rare case of spontaneous inguinal faecal fistula as a complication of incarcerated Richter's hernia with brief review of literature. *BMC Surg.* 2015;15(1):67.
6. Faridi SH, Siddiqui B, Khan MA, Anees A, Ali SA. Suprapubic fecal fistula due to Richter's inguinal hernia: a case report and review of literature. *Iran J Med Sci.* 2013;38(2):129.
7. Chen W, Liu L, Huang H, Jiang M, Zhang T. A case report of spontaneous umbilical enterocutaneous fistula resulting from an incarcerated Richter's hernia, with a brief literature review. *BMC Surg.* 2017;17(1):1-5.
8. Amjad AI, Qazi SH, Nazir Z. Enterocutaneous fistulae in children-a management challenge. *J Coll Physicians Surg Pak.* 2008;18(8):526.
9. Sharif M, Ijaz L, Iqbal S, Sheikh A. Enteroscrotal fistula: a rare complication of incarcerated inguinal hernia. *APSP J Case Rep.* 2010;1(2):21.
10. Karabulut R, Karakuş C, Hirfanoglu İ, Turan Ö, Türkyılmaz Z, Sönmez K, et al. Treatment of postoperative enterocutaneous fistulas with octreotide in two neonates. *Eur J Pediatr Surg.* 2008;18(1):56-8.