

Radiological Quiz

The insufflated balloon

Abdul Lateef Leghari,^{1*} Muhammad Bilal Mirza²

1. Medical College, Aga Khan University Hospital, Karachi

2. Department of Pediatric Surgery II, The Children's Hospital and the Institute of Child Health, Lahore

Cite as: Leghari A, Mirza M. The insufflated balloon. J Pediatr Adolesc Surg. 2024; 2:63-5.

This is an open-access article distributed under the terms of the Creative Commons Attribution License, which permits unrestricted use, distribution, and reproduction in any medium, provided the original work is properly cited (<https://creativecommons.org/licenses/by/4.0/>).

A one-day-old neonate presents in emergency with abdominal distension and failure to pass meconium. On clinical examination, there is abdominal distension, and perineal examination reveals an imperforate anus. The child is irritable, but hemodynamically stable. X-ray abdomen (erect position) is performed (Fig. 1).

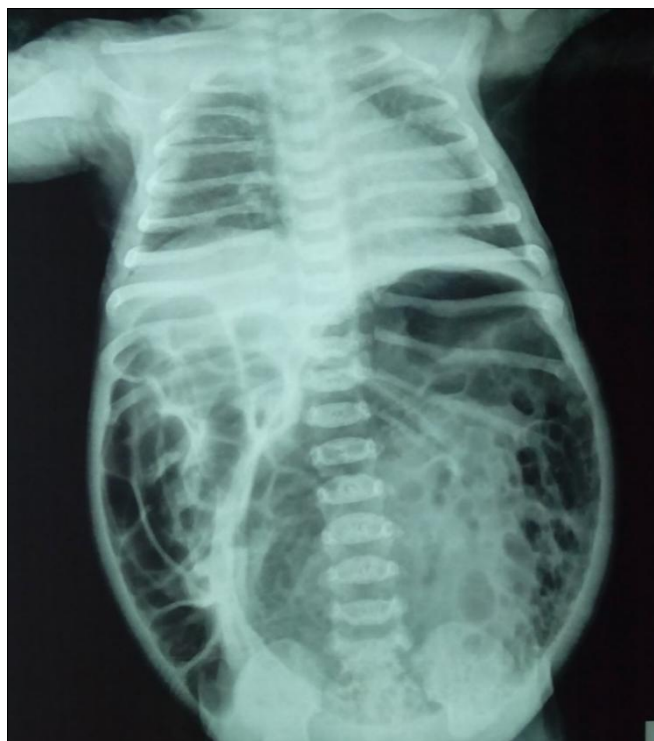

Figure 1: X-ray abdomen and chest

QUESTIONS

- i. What are the radiological findings in the radiograph above?
- ii. In view of the above findings what is the most likely diagnosis and why?
- iii. Which system of classification is preferred for your differential and what is it based on?

ANSWERS

i. The radiograph shows an X ray Abdomen and Chest of a baby

Cardiac size is normal.
Bilateral lung fields are clear.
Visualized bones appear normal.

There is a large lucency on left side of abdomen with some soap bubble appearance. The other bowel loops appear prominent, dilated, and displaced to the right side of abdominal cavity.

ii. The overall appearances are secondary to a complete congenital pouch colon (CPC) is to have a large bowel loop (visualized as the large gas shadow) occupying more than 1/2 of the abdominal width on the Xray with displacement of the rest of bowel to the right hemi abdomen in a patient with anorectal malformation.[1,2]

iii. Many classifications have been suggested for CPC, however the most widely used one was suggested by Narasimha Rao et al. on the basis of bowel length.[3]
Type 1: Normal colon is absent, and the ileum opens directly into the colonic pouch (Fig. 2).

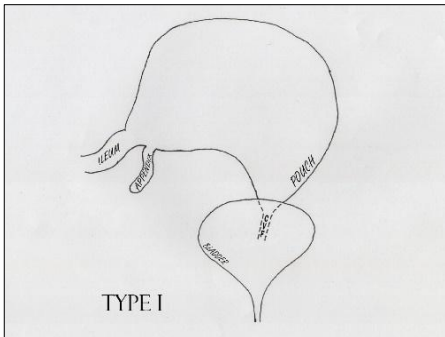


Figure 2: Type 1 CPC

Type 2: The ileum opens into a short segment of caecum, which then opens into the colonic pouch (Fig. 3).

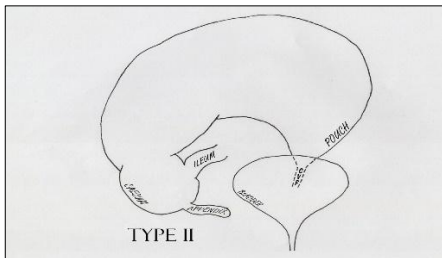


Figure 3: Type II CPC

Type 3: Presence of a significant length of normal colon between the ileum and the colonic pouch (Fig. 4).

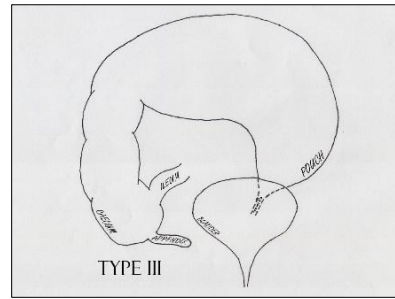


Figure 4: Type III CPC

Type 4: Presence of near-normal colon with only the terminal portion (rectum and sigmoid) converted into a pouch (Fig. 5).

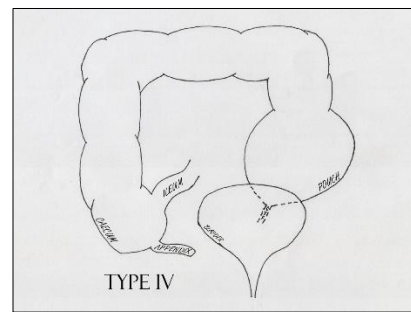


Figure 5: Type IV CPC

A simplified version of the same was later suggested where type I and II were categorized as “complete” and type III and IV as “incomplete” CPC.[4]

Complete CPC may produce a big gas filled lucency on abdominal radiograph as shown in Figure 1. However, incomplete CPC produces a localized small lucency on abdominal radiographs..

Conflict of Interest: Nil

Source of Support: Nil

Consent to Publication: Author(s) declared taking informed written consent for the publication of clinical photographs/material (if any used), from the legal guardian of the patient with an understanding that every effort will be made to conceal the identity of the patient, however it cannot be guaranteed.

Authors Contribution: Author(s) declared to fulfill authorship criteria as devised by ICMJE and approved the final version. Authorship declaration form, submitted by the author(s), is available with the editorial office.

Acknowledgements: None

REFERENCES

1. Wakhlu AK, Wakhlu A, Pandey A, Agarwal R, Tandon RK, Kureel SN. Congenital short colon. World J Surg. 1996; 20(1):107-14.
2. Chadha R, Khan NA. Congenital pouch colon. J Indian Assoc Pediatr Surg. 2017; 22(2):69.

The insufflated balloon

3. Narasimharao KL. Congenital short colon with imperforate anus (pouch colon syndrome). *Ann Paediatr Surg.* 1984; 1:159–67.
4. Gupta DK, Sharma S. 11 Congenital Pouch Colon. *Anorectal Malformations Child Embryol Diagnosis, Surg Treat Follow.* 2006; 211.