

Original Article

Management of chronic empyema thoracis in children, a single center retrospective observational study

Sudhir Singh, Nitin Pant, Survesh K Gupta, Jiledar Rawat*

Department of Pediatric Surgery, King George's Medical University, Lucknow, Uttar Pradesh, India, 226003

Cite as: Singh S, Pant N, Gupta S K, Rawat J. Management of chronic empyema thoracis in children, a single center retrospective observational study. J Pediatr Adolesc Surg. 2024; 2: 79-84.

This is an open-access article distributed under the terms of the Creative Commons Attribution License, which permits unrestricted use, distribution, and reproduction in any medium, provided the original work is properly cited (<https://creativecommons.org/licenses/by/4.0/>).

ABSTRACT

Background: Chronic empyema thoracis (CET) is common in developing and developed countries despite advancement in diagnostic and therapeutic technologies. Some of the cases of CET can be managed with antibiotics and tube drainage alone, some of them managed with less extensive surgical procedure like video-assisted thoracoscopic surgery (VATS) or open decortication alone, while some of the complicated cases need extensive decortication and debridement of necrotic lung tissue or lobectomy. Our aim is to present our experience of management of cases of chronic empyema thoracis in children.

Methods: This is a retrospective observational study of cases, managed at tertiary care center with chronic empyema thoracis. Records of cases of CET admitted, referred or transferred to department of pediatric surgery at our center over last three years were studied. Demographic data, clinical, radiological profile, surgical/ non-surgical intervention, hospital stay, aetiology, outcome was analysed. Follow up was up to the last recorded outpatient visit. This study is a retrospective observational study with small number of cases statistical tool are not used to draw any statistical interference.

Results: Twenty-nine cases with median age 3 years, male to female ratio was 25:4 were admitted over three years. Pre-operative bronchopleural fistula was seen in four. Five cases were managed conservatively, twenty underwent decortication alone while four cases required decortication along with lobectomy. Tuberculosis was detected in three cases. A pyogenic organism was identified in ten cases only. Post-operative ventilation was required in three patients. There was no mortality. All thrived well at 12-18 months follow up.

Conclusion: Management of chronic empyema should be case based. Cases of CET in children can managed with conservative (with appropriate drainage of cavity, proper antibiotics, and nutritional build-up of child), thoracotomy and decortications alone or some time removal of disease lung also required depending on clinical and radiological finding of cases.

Keywords: Bronchopleural fistula (BPF), Lobectomy, Open Decortications.

INTRODUCTION

The three stages of empyema thoracis namely exudative (Stage I), occurs if para-pneumonic effusion is not sufficiently treated. If there is further delay in proper management at this stage leads to progression of disease to fibrino-purulent (Stage II), or organized stage (Stage III) known as chronic empyema thoracis (CET) when it is lasting four weeks and beyond. [1] Intra-pleural fibrinolytic agents, can be used in early cases before significant collagen is laid down.[2] Video-assisted thoracoscopic surgery (VATS) approach has high success rate in early stages but in advanced staged cases, decortication is the commonly accepted treatment. [3] In

this study we are presenting our experience of management of cases of CET in children.

METHODS

This was a retrospective observational study of cases treated in three years' duration (Jan 2016-Dec 2018) of CET. Our center is a tertiary care hospital, generally cases are referred to us in late stage of empyema thoracis. Cases were studied of organized stage of CET admitted/referred/transfer to us age up to 12 years, where in addition to loculated pus or air, there was marked thickening of the pleura with encasement of the lung were present (Figure 1 and 2 A, B). Cases improved on conservative measures, those with no fever or

Correspondence*: Dr. Jiledar Rawat, Professor, Department of Pediatric Surgery, King George's Medical University, Lucknow, UP, India, 226003.

Email: sashvatsudhir@gmail.com

Submitted on: 10-08-2021

© 2024, Singh et al,

Accepted on: 13-11-2021

improving pattern of fever, cavity adequately drained by tube, improving general condition, no respiratory distress, good oral intake, small or no bronchopleural fistula (BPF) and no sepsis. Cases required operative measures, with persistent infection despite conservative management as exemplified by low general condition, fever, high counts (pattern not improving), and multi loculated collection, crowding of ribs, persistent large BPF and lung necrosis. The aims of surgical intervention were pleural debridement, to free encased lung parenchyma, closure of major air leaks and removal of unhealthy lung tissue wherever required. Standard open thoracotomy can achieve all the above-mentioned surgical goals.

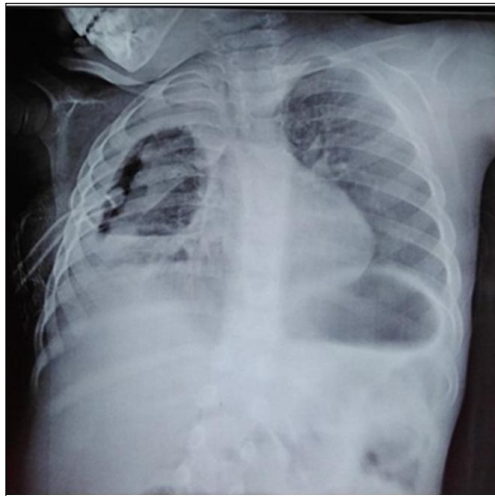


Figure 1: Chest X ray postero-anterior view of a child with right sided CET with ICD in situ showing scoliosis, crowding of rib, opacity at right lower zone and small pneumothorax along with collapse lung at upper zone.

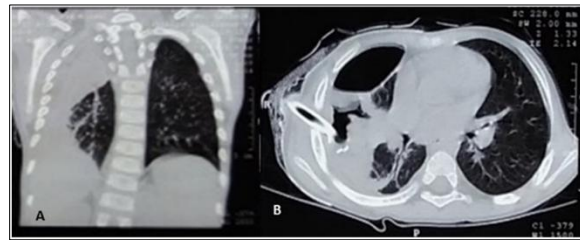


Figure 2: A and B, CECT Chest of a child showing CET right side with thick parietal and visceral pleura with underlying collapse of lung, and small pocket of air ICD in situ.

The technique of open thoracotomy and decortication was, the patient was in general anaesthesia under muscle relaxant, with endotracheal intubation. Single lung ventilation not done as lung expansion was needed during procedure to see the effectiveness of procedure and to see any air leak. The patient was placed laterally with the affected side up and the intercostal spaces increased by pad under the chest and the arm lifted up on head. A posterolateral thoracotomy is performed without excision of the rib through the 4th or 5th intercostal space depending on the radiological finding (Figure 3 A).

In some cases, where intercostal space was narrowed out in these access was gained by gradual retraction. After the pleural space was entered, pus samples taken for culture and sensitivity and pieces of pleura are taken for histopathological examination to rule out tuberculosis. Loculi were broken and the thick pleural peel was carefully removed from the surface of the entire lung releasing the encased lung.

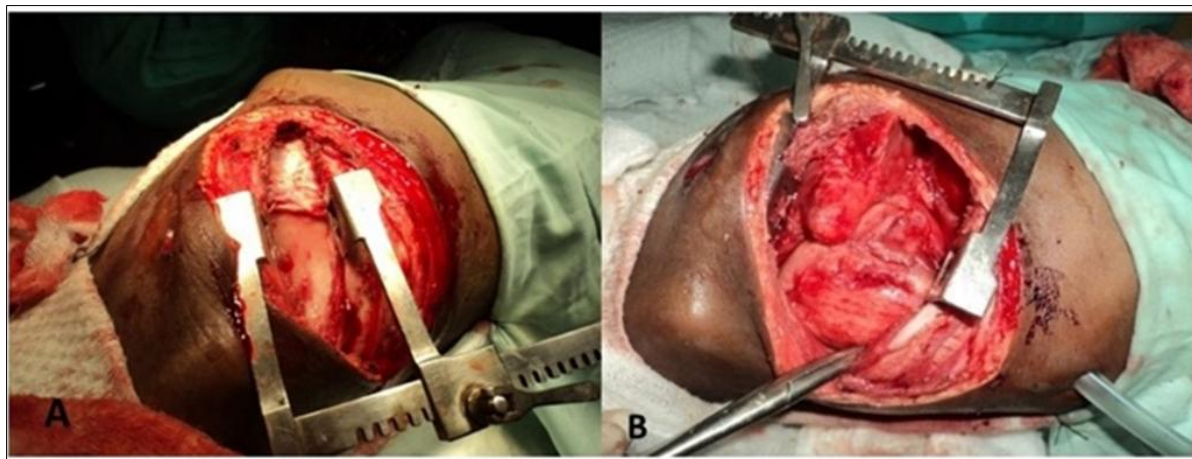


Figure 3: A and B- Intraoperative picture of open decortication, at start and after completion of decortication showing completely release lung

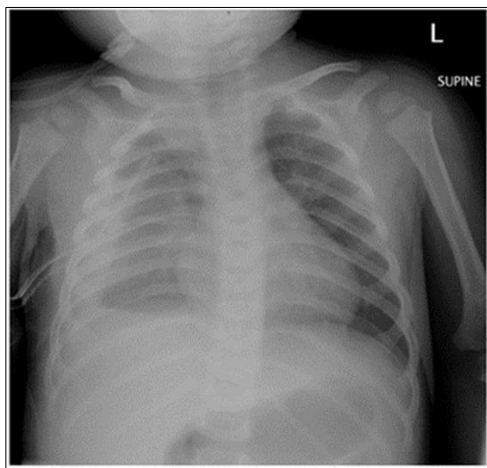


Figure 4: Post-operative Chest X ray showing expansion of lung with ICD in situ.

In cases where lung necrosis was present, in these cases lobectomy or debridement of necrotic tissue were done depending on extent of involvement. Some cases may have associated BPF, where there was a long history of persistent major air leak in intercostal drainage tube (ICD). Lung expansion should be assessed by asking the anaesthetist for manual ventilation (Figure 3 B). All significant minor air leaks were closed using absorbable (vicryl) suture and major leaks were closed with non-absorbable (prolene) suture.

Chest cavity was thoroughly irrigated with normal saline and two chest tubes of large bore were placed one directing apex and other towards base of pleural cavity. An intercostal local anaesthesia block was given before the chest closer. Patency of chest tube was insured to prevent pneumothorax and subcutaneous emphysema. In all of our cases clinical records were analysed for demographic data, aetiology, clinic-radiological profile, management, hospital stay, and outcome. Follow up were done with clinical examinations and chest X rays up to the last outpatient visit (Figure 4).

RESULTS

Total of 29 cases, managed in three years duration (Jan 2016-Dec 2018) were studied. In our study male to female ratio were 25:4. Age Range was from 5 months to 10 years (median 3 years) and distribution of age is shown in Table 1.

Table 1: Showing age distribution of chronic empyema cases

S. No	Age distribution	Number of cases (%)
1	< 3 years	10 (34%)
2	3-5 years	6 (20%)
3	5-12 years	13 (44%)
	Total cases	29

Our center is a tertiary care hospital, cases were referred to us in late stage of empyema thoracis. The duration of symptoms were 2 to 4 months (median=10 weeks). All the cases had ICD in situ at the time of presentation to us. Right side of empyema found in 19 cases and left side of empyema found only in 10 cases. In our study moderate to severe malnutrition was found in 70% of cases measured by mid arm circumference. Clinical presentation of cases shown in Table 2. Most of our cases 82% developed CET following post pneumonic effusion (Table 3), initially managed at other canter. One of cases was developed CET secondary to rupture right lobe liver abscess and one case was due to infected ruptured right thoracic hydrated cyst.

Table 2: Showing Clinical Presentations of chronic empyema cases

S. No	Clinical Presentations	Number of cases (%)
1	Fever	22 (75%)
2	Respiratory Distress	8 (27%)
3	Chest wall deformity	16 (55%)
4	Poor nutrition	26 (89%)
5	Air leaks in ICD tube	4 (13%)

Table 3: showing pathological profile of chronic empyema thoracic cases

S. No	Etiology of Chronic empyema	Numbers of cases (%)
1	Post pneumonic	24 (82%)
2	Tubercular	3 (10%)
3	Secondary to intra-plural rupture of liver abscess	1 (3%)
4	Secondary to rupture of an infected hydatid cyst	1 (3%)

All cases were evaluated with anteroposterior and lateral chest X rays, ultrasonography of chest to saw the collection in pleural cavity and to measure pleural thickness and contrast enhance tomography of chest (CECT) were done in all the cases. Radiological finding of chest of our cases at time of presentation to our department is given in table 4. Total of five cases improved conservatively, three of them had no fever and two had improving pattern of fever. All these five cases had improving general condition, no respiratory distress, good oral intake, no bronchopleural fistula (BPF) and no sepsis. Two of these cases repositioning of ICD tube was done and in three required ultrasound guided drainage of pus from pleural cavity. Nutritional build up along with chest physiotherapy was done in all cases. It's found that these cases improved on an average of fourteen days.

Thoracotomy was required in 24 cases, 20 of them managed with decortication alone while four cases required decortication along with lobectomy. One case of CET secondary to rupture right lobe liver abscess and one due to infected ruptured right thoracic hydrated cyst were successfully managed with thoracotomy and decortication and were well in up to 12 months of follow up.

In post-operative period four cases develops bronchopleural fistula (BPF), all of them improved on conservative measures over period of 2 weeks. Pyogenic bacteria (Staph. aureus and strep.) were cultured in 10 cases and tubercular aetiology documented in three cases in tissue biopsy. All 24 cases required intraoperative blood transfusion. Post-operative ventilation was required in three patients. There was no mortality. All thrived well at 12-18 months follow up.

Table 3: Radiological finding of chest of our cases (at time of presentation to our department)

Plain Chest X-ray	Ultrasonography	Contrast Enhance tomography
Collection in involved side (Pyothorax) in all (29) cases	Unilocular collection 21 cases	Thick pleura with enhancement in all (29) cases
Pyopneumothorax in five cases	Multilocular collection in eight cases	Multilocular collection 10 cases
Scoliosis and crowding of ribs in 15 cases	Thick pleura in all (29) cases	Rupture right lobe liver abscess and infected ruptured right thoracic hydrated cyst
		Necrotic tissue along with collection in 4 cases

DISCUSSION

Antibiotics and chest tube drainage is effective in stage I (exudative stage) of empyema.[4] In advanced stage there is dense adhesion in pleural cavity, so VATS is not quite effective in this stage of disease. VATS require advanced training and instruments in difficult cases and there are high chances of bleeding.[5] Fibrinolytic agent like streptokinase and urokinase is effective in stage II and early stage III. These agents are also not effective in advanced stage of CET. The disadvantage of fibrinolytic agents are anaphylaxis reactions, high cost and bleeding are reported.[6] In CET (Stage III or Organized stage of empyema) there is marked thickening of the pleura with encasement of the lung. The standard treatment of this stage of empyema is open surgical decortication. [7] The aims of the open surgical management are to control the infection and achieve a fully expanded lung. In ancient times ribs resection was advocated for CET management.[8] Now the purpose of treatments of CET (stage III) are to removal of the empyema space.

Decortication is the procedure of choice for patients with re-expandable underlying lung; and when BPF exists in the underlying lung, the fistula needs to be securely closed. [9]

All of 29 cases included in our study were presented to us in late stage III of CET, most of them in early stage of disease were managed at medical department or at other hospital. All of our cases were below the 12 years as be only including these cases in our study. At presentation 75% of our cases have recurrent fever, 27 % respiratory distress, 55 % chest wall deformity, 89% poor nutrition and in 13 % cases have preoperative air leak in ICD tubes. In our study malnutrition was found in up to 70% of cases as higher incidence of empyema cases were seen more often in malnourished children. [10] In our study, pleural fluid culture showed bacterial growth only in 10/29 (34%) of patients. Most common organism isolated was staphylococcus aureus as observed in other studies done developing countries. [11] The sterile sample might be due to high rate of antibiotics pre-treatment. All of our cases were evaluated with contrast enhanced computer tomography (CECT) thorax as it can measure the pleural thickening and inflammation. CECT thorax also delineate the pus collection any necrotic tissue and any lung parenchymal disease. CECT was able to detect the necrotic tissue in pleural cavity in four of cases. CECT is very important radiological investigation in cases of CET as found in others study.[12] CECT was able to diagnose one case developed CET after rupture right lobe liver abscess and one with infected ruptured right thoracic hydrated cyst.

Five of our cases at presentation were not in sepsis, no fever or fever with improving pattern, cavity adequately drained by ICD tube, improving general condition, no respiratory distress, good oral intake and small or no BPF. These cases were managed conservatively with proper drainage of cavity, antibiotics and nutritional build up. However, all of our cases were of advance stage of CTE so intra pleural fibrinolytic therapy and VATS were not tried. Thoracoscopic management of empyema is only effective in early stage (fibrino-purulent stage). [3] For management of late stage of empyema various modalities are available like fibrinolytic therapy and open decortication. However fibrinolytic therapy had disadvantages of high cost and allergic reactions.[6] Twenty-four of our cases fit in our criteria for surgical intervention, were managed with open thoracotomy and decortications. The key to successful management in these cases were lies in effective pleural evacuation and re- expansion of the lung.

Tubercular histology was found in three of our cases, in excised thick pleura tissue send for pathological examination. The overall burden of tuberculosis in a developing country like India, is around 10.2%, whereas tuberculous pleural effusion accounts for only 15.4% of the cases in children less than 10 years of age. [13]

Mycobacterium tuberculosis alone as a causative organism of empyema is rare. [14] There is often a diagnostic challenge to differentiate tuberculous from non-tuberculous empyema. Pleural biopsy is diagnostic in more than 90% of the cases, however acid-fast bacilli can be only detected in 25% of the cases of tubercular empyema.[15] In three of cases diagnosis was made of histopathology of pleural tissue. The suggested pathogenesis in these cases is rupture of a sub pleural caseous focus which results in delayed hypersensitivity reaction to mycobacterial antigens and rapidly progresses to form tubercular empyema followed by secondary bacterial growth.[16] We treated all three cases with four drug anti-tubercular chemotherapy in post-operative period.

Interestingly one of our cases developed CET secondary to rupture right lobe liver abscess and one case was due to infected ruptured right thoracic hydrated cyst. These cases were initially managed at other hospital and referred to us at late stage of organized CET. In a study on liver abscess in children showed that most common complication of liver abscess was right sided pleural effusion (22%), which resolved without any treatment if management of liver abscess done appropriately. [17] In our case liver abscess was not managed appropriately and leads to development of CET as described in other studies. [18] The child with ruptured and infected right side hydatid cyst of thorax presented to us like a CET, managed with open thoracotomy decortication and three months oral drug albendazole at dose of 10 mg /kg / day was given postoperatively.[19] Both two cases were successfully managed with thoracotomy and decortication and were well in up to 12 months of follow up.

REFERENCES

1. Shebl E, Paul M. Parapneumonic pleural effusions and empyema thoracis. [Updated 2020 Mar 6]. In: StatPearls [Internet]. Treasure Island (FL): StatPearls Publishing; 2020 Jan. (<https://www.ncbi.nlm.nih.gov/books/NBK534297/>)
2. Abu-Daff S, Maziak DE, Alshehab D, Threader J, Ivanovic J, Deslaurier V, et al. Intrapleural fibrinolytic therapy (IPFT) in loculated pleural effusions-analysis of predictors for failure of therapy and bleeding: a cohort study. *BMJ Open*. 2013; 3(2): e001887.
3. Hajjar WM, Ahmed I, Al-Nassar SA, Alsultan RK, Alwgait WA, Alkhalaf HH, et al. Video-assisted thoracoscopic decortication for the management of late stage pleural empyema, is it feasible?. *Ann Thorac Med*. 2016; 11:71-8.
4. Menon P, Kanojia RP, Rao KL. Empyema thoracis: Surgical management in children. *J Indian Assoc Pediatr Surg*. 2009; 14:85-93.
5. Subotic D, Lardinois D, Hojski A. Minimally invasive thoracic surgery for empyema. *Breathe*. 2018; 14:302-10.
6. Ahmed S, Azam H, Basheer I. Is open decortication superior to fibrinolytic therapy as a first line treatment in the management of pleural empyema? *Pak J Med Sci*. 2016; 32:329-32.
7. Shin J A, Chang Y S, Kim T H, Haam S J, Kim H J, Ahn C M, et al. Surgical decortication as the first-line treatment for pleural empyema. *J Thorac Cardiovasc Surg*. 2013; 145:933-9
8. S. A. Edaigbini, N. Anumenechi, V. I. Odigie, L. Khalid, and A. D. Ibrahim, "Open drainage for chronic empyema thoracis; clarifying misconceptions by report of two cases and review of literature," *Archives of International Surgery*. 2013; 3:161-5.
9. Kim BY, Oh BS, Jang WC, Min YI, Park YK, Park JC. Video-assisted thoracoscopic decortication for management of postpneumonic pleural empyema. *Am J Surg*. 2004; 188:321-4.
10. Satpathy SK, Behera CK, Nanda P. Outcome of parapneumonic empyema. *Indian J Pediatr*. 2005; 72:195-9.
11. Goyal V, Kumar A, Gupta M, Sandhu H P, Dhir S. Empyema Thoracis in Children: Still a challenge in developing countries. *African Journal of Paediatric Surgery*. 2014; 11:206-10.

In four of our cases require lobectomy due to necrotic lung parenchyma. As all of our cases were of advanced stage, during decortication thick parietal and visceral pleura were removed leads to bleeding, all of our cases require blood transfusion in intraoperative or just postoperative period. In postoperative period air leak in ICD tube usually stopped spontaneously within 48 hours. Sometime due to BPF there extended period air leak found. In four of our cases BPF developed in post-operative period that was healed spontaneously over an average period of 2 weeks.

CONCLUSION

Though no single procedure offers a solution for CET. Chronic empyema should be managed on merit basis. Selected cases can be managed conservatively while decortication usually suffices in most of cases. Decision to perform lobectomy might have to be taken intra-operatively in cases of unhealthy lobe.

Conflict of Interest: Nil

Source of Support: Nil

Consent to Publication: Author(s) declared taking informed written consent for the publication of clinical photographs /material (if any used), from the legal guardian of the patient with an understanding that every effort will be made to conceal the identity of the patient, however it cannot be guaranteed.

Authors Contribution: Author(s) declared to fulfill authorship criteria as devised by ICMJE and approved the final version. Authorship declaration form, submitted by the author(s), is available with the editorial office.

Acknowledgements: None

12. Singh AP, Shukla AK, Sharma P, Shukla J. Surgical management of stage III pediatric empyema thoracis. *Lung India*. 2018; 35:209-14.
13. A Kumar, D Gupta, S B Nagaraja, V Singh, GR Sethi, J Prasad. Updated national guidelines for pediatric tuberculosis in India, 2012. *Indian Pediatr*. 2013; 50:301-06.
14. M Zampoli, H J Zar. Empyema and parapneumonic effusions in children: an update. *SA Journal of Child Health*. 2007; 1:121-8.
15. Vorster MJ, Allwood BW, Diacon AH, Koegelenberg CF. Tuberculous pleural effusions: advances and controversies. *J Thorac Dis*. 2015; 7:981-91.
16. Intan HI, Othman N, Alsiddiq M FMF, Wan Afza F WZ, Lokman MN. The unexpected bilateral tuberculous empyema: a case report in a child. *Int J Health Res*. 2008; 1:40-4.
17. Salahi R, Dehghani SM, Salahi H, Bahador A, Abbasy HR, Salahi F. Liver abscess in children: A 10-year single centre experience. *Saudi Journal of Gastroenterology*. 2011; 17:199-202.
18. Darlington DC, Anitha FSG. Ruptured amoebic liver abscess with empyema thoracis - a case report. *Int Surg J*. 2017; 4:1801-2.
19. Sayir F, Cobanoglu U, Sehitogullari A. Surgical treatment of pulmonary hydatid cysts, which perforated to the pleura. *Eurasian J Med*. 2012; 44:79-83.