

## Original Article

# The spectrum of congenital malformations of the lung at a rural hospital

Pooja Kailas Bhole, Vivek Gharpure\*

Department of Surgery, Pravara Institute of Medical Sciences, Loni, Ahmednagar &  
Children's Surgical Hospital, Aurangabad

**Cite as:** Bhole PK, Gharpure V. The spectrum of congenital malformations of the lung at a rural hospital. J Pediatr Adolesc Surg. 2020; 1: ahead

This is an open-access article distributed under the terms of the Creative Commons Attribution License, which permits unrestricted use, distribution, and reproduction in any medium, provided the original work is properly cited (<https://creativecommons.org/licenses/by/4.0/>).

## ABSTRACT

**Background:** Congenital malformations of lung, such as congenital lobar emphysema, cystic adenomatoid malformation, bronchial cyst, pulmonary sequestration are of rare occurrence. However, our hospital being in a rural area attracts a large number of patients with complex malformations.

**Method:** This retrospective analysis is done to evaluate diagnostic accuracy, safety and efficacy and outcomes of open lung resections at a rural hospital.

**Results:** 16 children with congenital lung malformation underwent open resection in a rural hospital, with no mortality and minimal morbidity, no complications and more than 24 months follow-up.

**Conclusion:** Open lung resections are found to be safe, effective in a rural setting also.

**Keywords:** CPAM (Congenital pulmonary airway malformation), Pulmonary sequestration, Lobectomy, CLE (Congenital lobar emphysema), Lung resection, bronchogenic cyst, CCAM (Congenital cystic adenomatoid malformation), CTM (Congenital thoracic malformations), Extra-lobar, Intra-lobar, Posterolateral thoracotomy, lobectomy.

## INTRODUCTION

Surgery for congenital lung malformation is only 80 years old. First resection for congenital lobar emphysema was done in 1943 by gross and levis. Churchill was the first to perform lobectomy with hilar dissection. A wide range of congenital malformations of the lung, such as, congenital cystic adenomatoid malformation (CCAM), intra and extra-lobar pulmonary sequestration (PS), bronchogenic cysts, congenital large hyperlucent lobe (CLHL) or congenital lobar emphysema (CLE) and bronchial atresia, are included in the group 'Congenital Lung Malformations'. These are also called Congenital thoracic malformations, (CTM) by few researchers (1,2). CTMs account for 5–18% of all congenital abnormalities, have a cumulative incidence of 30–42 patients per 100,000 population (3).

There has been a dramatic increase in the number of publications on congenital thoracic malformations (CTM), as a result of advances in prenatal and postnatal diagnosis, improved perioperative management and postoperative care (4). Most patients are detected by antenatal ultrasound scan or MRI (5). About 10 % of congenital lung disorders are diagnosed at birth, while another 14 % show up by age of 15 years (6). Prenatal diagnosis can be missed and the condition detected later, either by chance or because of persistent respiratory symptoms.

Most babies diagnosed antenatally with a congenital lung disorder can be carried to full term unless there is risk of harm to mother. Fetal surgery has been advocated for CPAM with hydrops but is controversial. In complicated cases delivery at hospitals with a neo-

natal intensive care unit is convenient and safer. Many infants do well after delivery and remain asymptomatic for a long time. Complications may occur beyond infancy. Once diagnosis is established, management is carried out by neonatologists and paediatric surgeons.

The purpose of this study is to evaluate the diagnostic accuracy, safety and efficacy, outcomes of surgical interventions i.e., open lung resections carried out in children with congenital lung malformations at our hospital.

## METHODS

After receiving Institutional ethical committee approval, we started our study. This is a retrospective analysis conducted over a period of 10 years. All patients with congenital lung malformations, who underwent surgical resection were included. The study included 16 children between 1 month-11 years with follow-up till 2 years, respectively. Presentations of patients, investigations, surgical intervention, immediate and long-term outcomes were evaluated. All patients were included whose record was available. All patients were evaluated with CT chest before decision to operate upon them was taken. Blood transfusion was not required during or after surgery. Standard endotracheal anaesthesia was used. Posterolateral thoracotomy in fourth or fifth space was the incision of choice. Following exposure of lung hilum, vascular anatomy was ascertained. Lobectomy was carried out. Bronchial stump was closed with multiple figure of eight sutures. An intercostal drain was left. Drain was removed when remaining lung was seen to have completely expanded. We lie to present few important cases.

### Case number 1

B.Y. presented with respiratory distress of 5 days, at 1 month age. Air entry was reduced on left side and mediastinum was shifted to right. CXR showed hyperinflation on left side in Fig 1. CT showed features of CLE. He underwent LUL lobectomy. Post-op recovery was uneventful. He is asymptomatic 12 months after surgery. Figure 1.

### Case number 2

S, presented with recurrent cough and fever, for three months at 4 years. Air entry was reduced in right lower zone, with coarse crepitations. Investigations revealed persistent consolidation in RLL. CT showed CPAM in RLL. He underwent RLL lobectomy and made uneventful recovery. He is well 18 months after surgery. Figure 2.

### Case number 3

S.R. presented at 5 months with cough of two weeks duration. Air entry was equal on both sides. She was

found to have an opacity in left lower chest on x-ray. CT revealed Congenital extralobar pulmonary sequestration, in left hemithorax. She underwent resection. Sequestration had separate blood supply from aorta. She made an uneventful recovery. Figure 3.

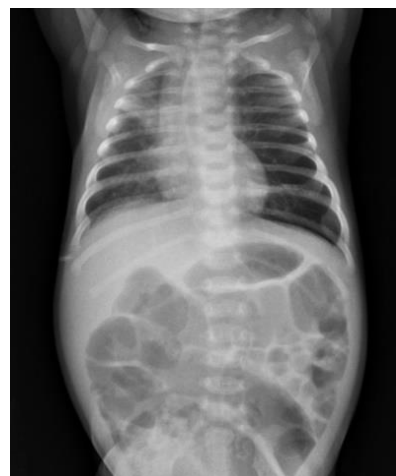

Figure 1: The x-ray showing Congenital lobar emphysema LUL

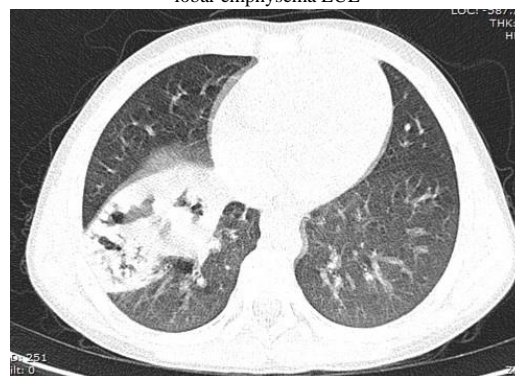


Figure 2: The CT scan showing CPAM in Right Lower Lobe.

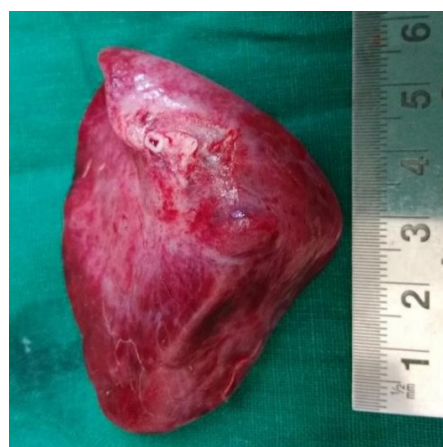

Figure 3: Gross pathological image showing Extralobar sequestration Left hemithorax is shown

## RESULTS

There were 8 boys and 8 girls, totaling to 16. Male: female ratio is 1:1. 8/16 were below one year out of

which 2 patients were neonates. Routine investigations were within normal limits. All patients underwent open thoracotomy. Hospital stay after surgery averaged 9.2 days (7 to 11). There were no operative or perioperative complications. There was no mortality. All wounds healed by primary intention.

Patients were called for follow-up at one, three months and later, telephonic follow-up was obtained every 3 months for next 2 years. Details of patients with diagnoses and outcomes are presented in Table 1.

Table: 1

| Sr no | Name | Age (yrs.) | Sex | Diagnosis                    | Procedure     | Outcome | Follow-up           |
|-------|------|------------|-----|------------------------------|---------------|---------|---------------------|
| 1     | S    | 2/12       | M   | Extralobar sequestration     | Resection     | Good    | Normal at 11 months |
| 2     | S    | 4          | F   | RLL CPAM                     | Lobectomy     | Good    | Normal at 12 months |
| 3     | T    | 3/52       | F   | LUL CLE                      | Lobectomy     | Good    | Normal at 6 months  |
| 4     | R    | 1/12       | M   | LUL CLE                      | Lobectomy     | Good    | Normal at 24 months |
| 5     | B    | 3          | F   | LLL CPAM                     | Lobectomy     | Good    | Normal 12 months    |
| 6     | A    | 2          | F   | RUL CPAM                     | Lobectomy     | Good    | Normal at 6 months  |
| 7     | A    | 1          | F   | LUL CLE                      | Lobectomy     | Good    | Normal at 18 months |
| 8     | A    | 8          | M   | RLL CPAM                     | Lobectomy     | Good    | Normal at 12 months |
| 9     | B.Y. | 1/12`      | M   | LUL CLE                      | Lobectomy     | Good    | Normal at 6 months  |
| 10    | A    | 4/12       | M   | LUL CLE                      | Lobectomy     | Good    | Normal t 6 months   |
| 11    | S.R. | 5/12       | F   | Extralobar sequestration     | Resection     | Good    | Normal at 36 months |
| 12    | B.N. | 6          | M   | RLL,intralobar sequestration | RLL lobectomy | Good    | Normal at 72 months |
| 13    | P.D. | 2          | F   | Lung Cyst LUL                | LUL lobectomy | Good    | Normal at 60 months |
| 14    | Q.A. | 11         | F   | CPAM, RUL                    | RUL lobectomy | Good    | Normal at 60 months |
| 15    | S.D. | 2          | M   | Bronchial cyst               | Excision      | Good    | Normal at 12 months |
| 16    | S.N  | 1          | M   | Bronchogenic cyst            | Excision      | Good    | Normal at 72 months |

**DISCUSSION**

There are few classification systems used for these congenital lung malformations. Congenital lung malformations also known as congenital thoracic malformations are of rare occurrence. It covers a wide range of disorders, such as, congenital cystic adenomatoid malformation (CCAM), intra and extra-lobar pulmonary sequestration (PS), bronchogenic cysts, Congenital Lobar Emphysema and bronchial atresia. Lung agenesis-hypoplasia complex (pulmonary underdevelopment), congenital pulmonary airway malformations (CPAMs), CLE, bronchial atresia, and bronchogenic cysts is included in bronchopulmonary anomalies. The congenital anomalies are uncommon, yet they can cause significant morbidity and mortality such as respiratory failure, haemorrhage and infection. If not recognised incor-

rect invention may be done. Bronchopulmonary abnormalities can be accompanied by vascular abnormalities in some cases i.e., pulmonary vascular abnormalities with pulmonary hypoplasia or agenesis, or a systemic arterial supply to a small cyst CPAM (“hybrid” lesion).

Detection of CPAMS in increasing number of patients is possible on combining modern high frequency probes to routine ultrasound screening for all pregnancies. With magnetic resonance imaging (MRI), there is better visualization of abnormal structures, airway and vascular anomalies. (8)

Prenatal management includes maternal administration of steroids to improve lung maturation. In patients with hydrops, amniotic shunts have been done. Sclerotherapy has also been done in selected patients where equipment and trained staff are available. We did not

need to perform antenatal intervention in any of our patients. For optimal prenatal counselling and appropriate peri- and postnatal management it is essential to recognizing the antenatal and postnatal imaging features of above abnormalities is essential. CT scan and X ray are reliable diagnostic investigations. Few require respiratory support or oxygen at birth. Most neonates (>75%) remain asymptomatic (9). Symptoms are reported at an average age of around 7 months (10). A fast-growing CPAM may cause mediastinal shift and resulting in development of polyhydramnios and hydrops (11,12). Presence of large lesions, bilateral lung involvement, and hydrops indicate poor prognosis (12,13,14,15). It is predicted by measurement of mass size, and include a mass-thorax ratio of more than 0.56 (13) or a CPAM volume ratio (i.e., volume of the mass divided by head circumference) greater than 1.6 (14). Most children with congenital lung malformations present with respiratory symptoms, depending on size and location of malformation, and the amount of functioning lung tissue. We must not miss the presence of hydrops, the presence or absence of a systemic arterial supply, mass effect on the mediastinum, and other associated organ system anomalies while radiological evaluation of any fetal chest mass. Minimally invasive procedures or open foetal surgery can be considered if expertise and equipment is available. For congenital airway malformations, expectant management is appropriate for the nonhydropic fetus, whereas the survival of fetuses with hydrops may improve with fetal intervention (13). If the mass is predominantly a single cyst, thoracoamniotic shunting may be considered as an option. After 32 weeks gestation, if the fetus is maintained on placental circulation surgical resection of the mass may be possible, using an ex-utero intrapartum treatment ("EXIT") procedure (14). The mortality rate may be as low as 5% or less when fetal distress is not evident (15). Although the definitive treatment of CCAM postnatally is surgery, there is a controversy whether or not asymptomatic cases be subjected to surgery (16). A lobectomy is almost always done for congenital lobar emphysema, Cystic Pulmonary Adenomatoid Malformation and intra-lobar sequestration. Resection is necessary to avoid further expansion of affected lobe and compression of normal lung.

CPAMs are usually discovered from neonatal period to 2 years of age, if not recognized antenatally, manifests as respiratory difficulty or infection. Surgical treatment consists of lobectomy or segmental resection is generally done in symptomatic infants who are diagnosed postnatally (14). Delayed elective resection can be done to avoid recurrent infection and to eliminate a small risk of malignancy (14).

Bronchogenic cyst can be resected thoracoscopically depending on the location of the bronchogenic cyst and the patients' age. In patients with CLE, who demonstrate mild respiratory distress, treatment can be con-

servative, with low-volume and low-pressure ventilatory support given as required. Whereas, with more severe neonatal respiratory distress, emergent surgical resection of the affected lobe may be needed (15). Most recognized pulmonary sequestrations are surgically resected electively, even in asymptomatic patients due to the risk of infection, haemorrhage, and malignancy (14).

Although Ji-Hyun Lee et al have reported that, "lung protective ventilation decreases the postoperative pulmonary complications", we did not use ventilation in any of the patients, except two, who required only CPAP (18). We recommend the following algorithm for postnatal management of a child diagnosed to have congenital lung malformation. See Figure 4.

All our resections have been open. A published large series showing video assisted thoracotomy (VATS) to be a safe and effective technique in experienced hands (19 - 23). VATS is only limited to non-anatomical resections of small peripheral lesions or complete anatomical lobectomies (19,21). Having said that, open thoracotomy is quicker, cheaper and safer in most surgeons' hands. The outcome of lobectomy/pneumonectomy is good in children. In lobectomy the remaining lung grows and expands adequately and total lung volume and pulmonary function return to normal (19). This is vigorous in very young as new acini and alveoli form upto 5 years age (20). Post-resection majority of patients has an excellent result. In younger groups it is noted, lower ratio of residual volume to total lung capacity and higher maximum breathing capacity. This suggests that hyperplasia rather than overdistension occurs in the remaining lung (20). According to our experience, few of our patients presented with one of the following symptoms of cough, fever, respiratory distress remainder were diagnosed on antenatal scan and followed up. After stabilizing, we carried out chest x-ray as a screening investigation. Those who had a radiological finding, were then sent for a contrast CT scan of chest. After CT scan confirmed the presence of malformation, patients were prepared for surgery, and optimized. All procedures were carried out under general anaesthesia, with endotracheal intubation. Double lumen endotracheal tubes were not used in any patient. Chest tube and underwater seal were utilized in all patients, with appropriate care. No patient required post-operative mechanical ventilation. There were no deaths or post-operative infections in any patient. Limitations of the study are, this being a rural hospital, we do not have paediatric thoracoscopic equipment, and we had to perform open thoracotomy for every patient. Secondly, we did not encounter any antenatal patient with complications of CPAM, such as hydrops and antenatal intervention were not done in any patient. Regular follow up was done by phone as patients come from remote areas and cannot visit hospital frequently. Furthermore, we were restricted to information present in the medical records.

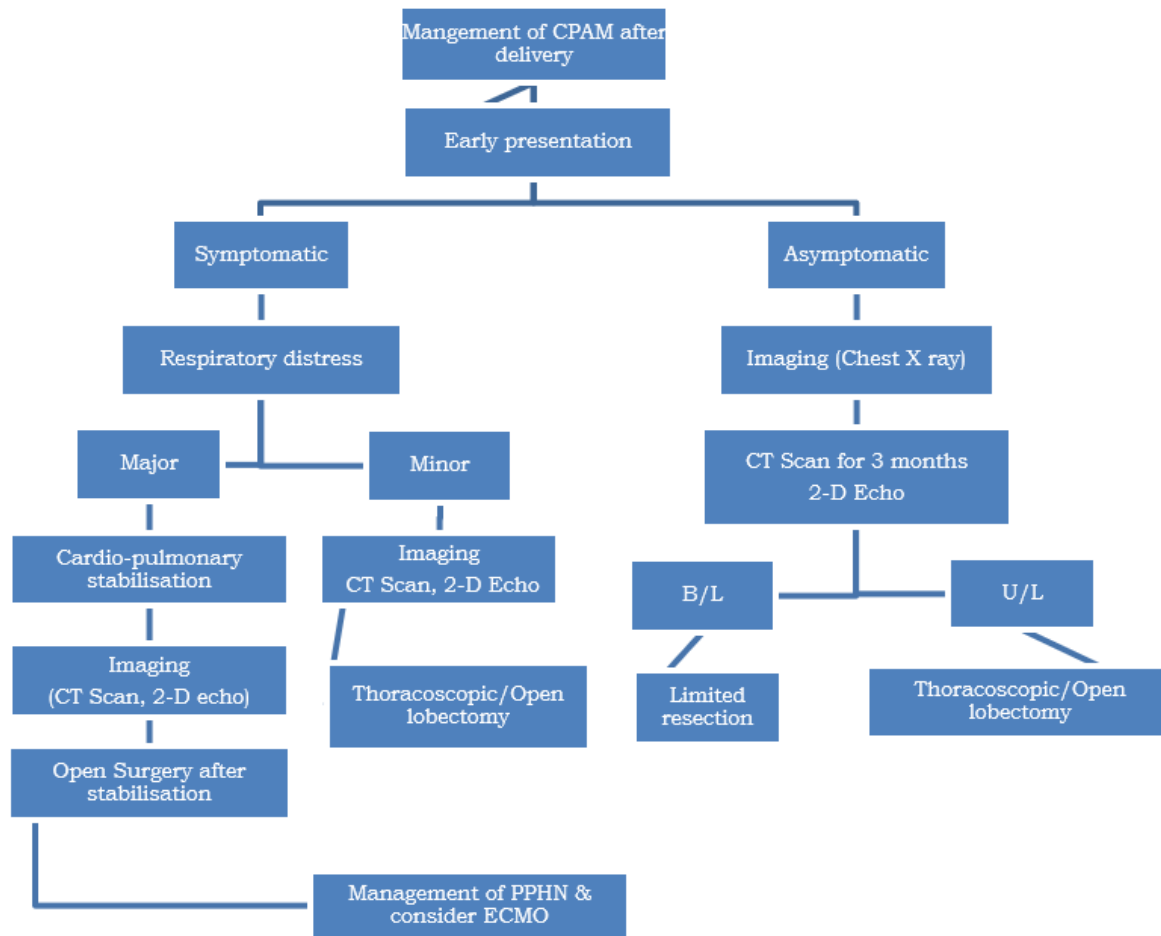


Figure 4: Algorithm

## CONCLUSION

Pulmonary resection is necessary for children with congenital lung malformations. Surgery should be done as soon as diagnosis is made, as it is safe, does not require intensive post-operative care and ventilation and can be carried out at well-equipped hospital by a properly trained paediatric surgeon. Hema Kini, Saraswathy Sreeram, Saumya Shukla (21), Katrina J Sullivan, Michelle Li, Sarah Haworth (22), Jessica Kapralik, Carolyn Wayne, Emily Chan, Ahmed Nasr (23), Meenu Singh, Sudeshna Mitra, Lata Kumar (16) have mentioned similar approach to such patients.

Prevention of infection and cancer, improved restoration of lung volume and fewer complications also favour elective early surgery.

Open resection of congenital lung lesions is a simple, quicker, safe and inexpensive technique, which

produces excellent results both in the short and medium term. It produces good outcomes and needs limited resources and expertise is achieved earlier. We feel that currently, this should remain the “gold standard” against which newer techniques must be judged.

**Conflict of Interest:** None.

**Consent to Publication:** Author(s) declared taking informed written consent for the publication of clinical photographs/material (if any used), from the legal guardian of the patient with an understanding that every effort will be made to conceal the identity of the patient, however it cannot be guaranteed.

**Authors Contribution:** Author(s) declared to fulfill authorship criteria as devised by ICMJE and approved the final version. Authorship declaration form, submitted by the author(s), is available with the editorial office.

**Acknowledgements:** None.

## REFERENCES

1. Stocker JT. Congenital pulmonary airway malformation – a new name for and an expanded

classification of congenital cystic adenomatoid malformation of the lung. Symposium 24:

- nonneoplastic lung disease. *Histopathology*. (2002) 41(Suppl. 2):424–30.
2. Bush A, Abel RM, Chitty LS, Harcourt J, Hewitt R, Nicholson AG. Congenital lung disease. In: Wilmott RW, Deterding RR, Li A, Ratjen F, Sly P, Zar H, Bush A, editors. *Kendig's Disorders of the Respiratory Tract in Children*. Philadelphia, PA: Elsevier; (2019). P 289–337.
  3. Andrade CF, Ferreira HP, Fischer GB. Congenital lung malformations. *J Bras Pneumol*. (2011) 37:259–71.10.1590/S1806-37132011000200017].
  4. Federica Annunziata, Andrew Bush, Francesco Borgia, Et al., *Congenital Lung Malformations: Unresolved Issues and Unanswered Questions*, *frontiers in paediatrics*; 7: 239, page 1, vol: issue, Jun 13, 2019, doi: 10.3389/fped.2019.00239.
  5. <https://www.childrens.com/specialties-services/conditions/congenital-lung-disorders>, page 3
  6. <https://www.childrens.com/specialties-services/conditions/congenital-lung-disorders>, page 1.
  7. Ruchonnet-Mbtrailler I, Leroi-terquem E, Stirnemann J et.al., Neonatal outcomes of prenatally diagnosed congenital pulmonary malformations, *Pediatrics* 2014 133 (5); e1285-91 (issn1098-4275)
  8. David M, Lamas-Pinheiro R, Henriques-Coelho T. Et al., Prenatal and Postnatal Management of Congenital Pulmonary Airway Malformation, *Neonatology* 2016;110:101-115, page no 6.
  9. Calvert JK, Lakhoo K. Antenatally suspected congenital cystic adenomatoid malformation of the lung: postnatal investigation and timing of surgery. *J Pediatr Surg*. (2007) 42:411–4. 10.1016/j.jpedsurg.2006.10.015.
  10. Baird R, Puligandla PS, Laberge JM. Congenital lung malformations: informing best practice. *Semin Pediatr Surg*. (2014) 23:270–7. 10.1053/j.sempedsurg.2014.09.007.
  11. Adzick NS, Harrison MR, Glick PL et al.. Fetal cystic adenomatoid malformation: prenatal diagnosis and natural history. *J PediatrSurg* 1985;20(5):483–488.
  12. Adzick NS, Harrison MR, Crombleholme TM, Flake AW, Howell LJ. Fetal lung lesions: management and outcome. *Am J ObstetGynecol* 1998;179(4):884–889.
  13. Vu L, Tsao KJ, Lee H et al. Characteristics of congenital cystic adenomatoid malformations associated with nonimmune hydrops and outcome. *J PediatrSurg* 2007;42(8):1351–1356.
  14. Azizkhan RG, Crombleholme TM. Congenital cystic lung disease: contemporary antenatal and postnatal management. *PediatrSurg Int* 2008;24(6):643–657.
  15. Davenport M, Warne SA, Cacciaguerra S, Patel S, Greenough A, Nicolaides K. Current outcome of antenally diagnosed cystic lung disease. *J PediatrSurg* 2004;39(4):549–556.
  16. Meenu Singh, Sudeshna Mitra, Lata Kumar Et al., Congenital Cystadenomatoid Malformation of Lung. *Indian Pediatrics* 2000;37: 1269-1274.10/31/2020.
  17. Eber E. Antenatal diagnosis of congenital thoracic malformations: early surgery, late surgery, or no surgery? *Semin Respir Crit Care Med* 2007;28(3):355–366.
  18. Lee JH, Bae JI, Jang YE, Kim EH, Kim HS, Kim JT. Lung protective ventilation during pulmonary resection in children: a prospective, single-centre, randomised controlled trial. *Br J Anaesth*. 2019 May;122(5):692-701. Doi: 10.1016/j.bja.2019.02.013. Epub 2019 Mar 8. PMID: 30916035.
  19. Filler J. Effects upon pulmonary function of lobectomy performed during childhood. *Am Rev Respir Dis* 1964; 89: 801-810.
  20. Peters RM, Wilcox BR, Schultz EH. Pulmonary resection in children: Long-term effect on function and lung growth. *Ann Surg* 1964; 159: 652-660.
  21. Hema Kini, Saraswathy Sreeram, Saumya Shukla. Congenital Pulmonary Airway Malformation – 19-Year Experience from a Tertiary Care Center in India. *Fetal Pediatr Pathol*. 2019 Dec;38(6):449-459. Doi: 10.1080/15513815.2019.1613703. Epub 2019 May 14.
  22. Katrina J Sullivan, Michelle Li, Sarah Haworth. Optimal age for elective surgery of asymptomatic congenital pulmonary airway malformation: a metaanalysis. *Pediatr Surg Int*. 2017 Jun;33(6):665-675.DOI: 10.1007/s00383-017-4079-2.
  23. Jessica Kapralik, Carolyn Wayne, Emily Chan, Ahmed Nasr. Surgical versus conservative management of congenital pulmonary airway malformation in children: A systematic review and meta-analysis. *J PediatrSurg* 2016 Mar;51(3):508-12. Doi: 10.1016/j.jpedsurg.2015.11.022..