

Case Report

Inflammatory myofibroblastic tumor of caecum presenting as recurrent intussusception: A case report

Aditya Pratap Singh,¹ Dinesh Kumar Barolia,^{2*} Harsha Vinod Bathia,³ Vipal H Parmar,⁴
Bhavana Asit Mehta,⁵ Shraddha Mehta,⁶

1. Department of Paediatric Surgery, Bhagwan Mahavir Hospital, Mahavir Nagar, Sumerpur, District – Pali, Rajasthan, India
2. Department of Paediatric Surgery, Sir Padampat Mother and Child Health Institute, S.M.S. Medical College, Jaipur, Rajasthan, India, 313001.
3. Consultant, Department of Anaesthesia, Bhagwan Mahavir Hospital, Mahavir Nagar, Sumerpur, District – Pali, Rajasthan, India
4. Consultant Histopathologist at Neuberg Supratech References Laboratories, Ahmedabad (NSRL)
5. Department of Histoanatomic Pathology Department, Neuberg Supratech Reference Laboratory, Ahmedabad, Gujarat, India
6. Department of Pathology, Bhagwan Mahavir Hospital, Mahavir Nagar, Sumerpur, District – Pali, Rajasthan, India

Cite as: Singh AP, Barolia DK, Bathia HV, Parmar VH, Mehta BA, Mehta S. Inflammatory myofibroblastic tumor of caecum presenting as recurrent intussusception: A case report. J Pediatr Adolesc Surg. 2020; 1: 92-94.

This is an open-access article distributed under the terms of the Creative Commons Attribution License, which permits unrestricted use, distribution, and reproduction in any medium, provided the original work is properly cited (<https://creativecommons.org/licenses/by/4.0/>).

ABSTRACT

Background: Inflammatory myofibroblastic tumor is an uncommon tumor. It commonly affects the lung but it can be found anywhere in the body.

Case Presentation: We are reporting a case of caecal mass presenting as recurrent intussusceptions. Histopathology and immunohistochemistry confirmed it to be an inflammatory myofibroblastic tumor of caecum. Immunohistochemistry of tumor cells were positive for vimentin, smooth muscle actin, MIB 1, and CD 45 in lymphoid cells in the stroma of the tumor.

Conclusion: Recurrent intussusception should be kept as one of the differential diagnosis in patient with caecal mass with recurrent abdominal pain. Inflammatory myofibroblastic tumor of the caecum is unusual in paediatric patients and may present as recurrent intussusception.

Keywords: Caecum, Desmin, Immunohistochemistry, Inflammatory tumor, Myofibroblastic tumor, Pseudotumor, Recurrent intussusception, Spindle cell tumor, Vimentin.

INTRODUCTION

Intussusception is telescoping of proximal bowel in distal. It was first reported by the Scottish surgeon James Hunter in 1793. [1] Lymphoid hyperplasia of Peyer patches, Meckel's diverticulum, viral infections, enteric duplication, cystic fibrosis, post-operative, Henoch-Schönlein purpura, Peutz-Jegher syndrome, familial polyposis and nephritic syndrome are the causes of intussusception in paediatric patients. [1-4] Inflammatory

myofibroblastic tumor is the rare cause of recurrent intussusception. Inflammatory myofibroblastic tumor is a mesenchymal spindle cell tumor. It is composed of myofibroblastic spindle cells (elongated and fusiform) which are infiltrated by plasma cells, lymphocytes, macrophages, and eosinophils. Rearrangement of the anaplastic lymphoma kinase (ALK) locus on chromosome 2p23 present in fifty percent cases of inflammatory myofibroblastic tumor, [5,6] It shows a slight female preponderance. Most of the cases are diagnosed in the first two

decades of life. Inflammatory myofibroblastic tumor of gastrointestinal tract may present with pain abdomen, obstruction, haemorrhage, intussusception etc. [7-9].

CASE REPORT

A 2-year old girl presented with recurrent abdominal pain for one and a half years. There was no history of nausea, vomiting, fever, diarrhoea, blood in stool and burning micturition. She had a history of pneumatic reduction of intussusception at the age of 9 months for pain abdomen. She got relief after pneumatic reduction, but after six months of reduction, she had complained of recurrent pain abdomen. At that time she took analgesic and antispasmodic medication from local pharmacy without any investigation and consultation. She became comfort after taking medication. At the age of two years, she came to our institute with abdominal pain.

Radial pulse was 97 per minute, regular with good volume, respiratory rate was 37 per minute. She was averagely nourished. On inspection, abdomen was flat, no abdominal fullness, no visible lump or visible peristalsis, and no scar mark. Umbilicus was centrally placed. There was no guarding, no rigidity, and no tenderness on palpation. No lump was detected on superficial palpation of abdomen. On deep palpation, lump was felt in the right lower quadrant. Ultrasonography showed target sign and diagnosis of recurrent intussusception was made. CT scan was not done because of poor socioeconomic condition of patient. All routine blood investigations like complete blood count, serum electrolytes, blood sugar, renal function tests, and liver function tests were within normal limits. Viral markers were negative. Due to history of recurrent abdominal pain and on the basis of ultrasonography finding, we planned exploration. Before exploration full informed and written consent was taken from parents. And all merits and demerits were explained. Exploration was done by right transverse supraumbilical incision. There was no telescoping of bowel but there was a palpable mass in the caecum (2.5 cm x 2.5 cm size, fixed in the wall of caecum) and edema was present at ileocaecal junction, suggesting reduced intussusception and caecal mass as the lead point. We did resection of the caecum and ileo-ascending anastomosis was done. Oral feeding was started after five days of surgery. The post-operative period was uneventful. There was no complaint of pain abdomen, vomiting, and blood in stool in six month follow up.

Histopathology of resected caecal swelling showed a spindle cell tumor. It is very difficult to classify the spindle cell tumor by eosin and hematoxylin staining. Spindle cell tumor was not a definitive diagnosis. The specimen was further evaluated. It was vimentin-positive, focally positive for smooth muscle actin, MIB1 positive, and CD 45 positive in lymphoid cells in the stroma of the tumor. Other findings in immunohistochemistry were negative for CD 34, CD 117, desmin, S 100, ALK1, DOG 1, H-Caldesmon. All these findings of immunohisto-

chemistry were suggestive of inflammatory myofibroblastic tumor or inflammatory pseudotumor.

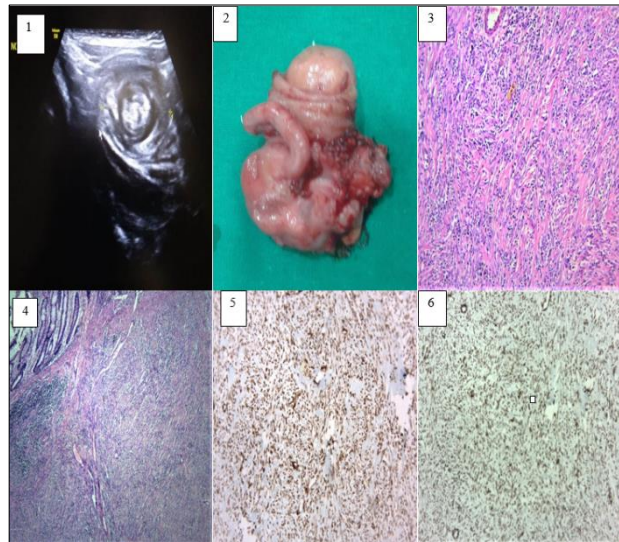


Figure: 1) Ultrasonography showed the target sign.
 2) Showed excised specimen of caecum containing mass.
 3 & 4) Hematoxylin and Eosin stained slide of biopsy showing fascicles of spindle cells with intervening areas of hyalinisation, collagenisation, and foci of calcification. Stroma shows inflammatory cells infiltration.
 5) IHC showed Vimentin positive slide.
 6) IHC showed SMA (smooth muscle actin) positive slide

DISCUSSION

Inflammatory myofibroblastic tumor is a low-grade or benign (intermediate variety) spindle cell tumor. It does not show distant metastasis, but it may have a tendency of local recurrence. [10] Inflammatory myofibroblastic tumor or inflammatory pseudotumor appears like malignant tumor clinically or radiologically. It consists of inflammatory cells like plasma cells, lymphocytes, macrophages, eosinophils, and myofibroblast. The term inflammatory pseudotumor was coined by Umiker and Iverson in 1954 because these tumors clinically and radiologically look like malignant tumors. [11] The gastrointestinal tract is an uncommon site of inflammatory pseudotumors. The stomach is commonly affected in the gastrointestinal tract. Small bowel, large bowel, and oesophagus are affected in decreasing order. [12] Inflammatory myofibroblastic tumor of gastrointestinal tract presents with pain abdomen, abdominal lump, dysphagia, intestinal obstruction, GIT bleed. [13] In our case, the patient presented with abdominal pain most probably due to recurrent intussusception. She had documented evidence of intussusception twice. Inflammatory myofibroblastic tumor was the leading point in recurrent intussusception in our case. Mehra SK et al. concluded in their study that timely management of intussusception can improve the outcome and reduce the need of extensive intervention during surgery. [14] To avoid major complication we did exploration on the basis of clinical and radiological findings.

In this modern era of super technology immunohistochemistry (IHC) has the new diagnostic value to reach the specific diagnosis after histopathological diagnosis. Differentiation of inflammatory myofibroblastic tumor from other spindle cell tumors is very difficult only with histopathological study. Immunohistochemistry and cytogenetic study help to classify the spindle cell tumor. Inflammatory myofibroblastic tumor shows positivity for desmin, vimentin, smooth-muscle-actin, muscle-specific actin, and activin receptor-like kinase 1 (ALK-1). [15] In our case tumor was positive for vimentin, smooth muscle actin, MIB1, and CD 45 in lymphoid cells of the stroma and negative for CD 34, CD 117, desmin, S 100, ALK1, DOG 1, H-Caldesmon.

Complete surgical resection of the tumor is the preferred surgical management. Nonsteroidal anti-inflammatory drugs and corticosteroid therapy may be used to reduce the tumor size. Thalidomide is also a reported drug that is used in the inflammatory myofibroblastic tumor. In specific circumstances when complete excision is not possible than radiotherapy can be used for residual tumor. Though a relatively benign neoplasm, reported

recurrence in the gastrointestinal tract is 18% to 40%. [16]

In conclusion, inflammatory myofibroblastic tumor of the caecum is unusual in paediatric patients and may present as recurrent intussusception. The inflammatory myofibroblastic tumor should be kept as a differential diagnosis whenever a patient presents with recurrent intussusception due to caecal mass.

Conflict of Interest: Nil

Source of Support: Nil

Consent to Publication: Author(s) declared taking informed written consent for the publication of clinical photographs/material (if any used), from the legal guardian of the patient with an understanding that every effort will be made to conceal the identity of the patient, however it cannot be guaranteed.

Authors Contribution: Author(s) declared to fulfill authorship criteria as devised by ICMJE and approved the final version. Authorship declaration form, submitted by the author(s), is available with the editorial office.

Acknowledgements: None

REFERENCES

1. Applegate KE. Intussusception in children: evidence-based diagnosis and treatment. *Pediatr Radiol.* 2009; 39 (suppl 2): S140-143.
2. Zhang Y, Zou W, Zhang Y, Ye W, Chen X, Liu Q, et al. Reducing Antibiotic Use for Young Children with Intussusception following Successful Air Enema Reduction. *PLoS One.* 2015; 10(11): e0142999.
3. Singh AP, Gupta AK, Barolia DK, Ansari M. Post-Operative Intussusception in a Child after Pseudo Cyst of Pancreas Excision. *National J Health Sci.* 2018; 3 (2):61-66.
4. Ito Y, Kusakawa I, Murata Y, Ukiyama E, Kawase H, Kamagata S, et al. Japanese guidelines for the management of intussusception in children, 2011. *Pediatr Int.* 2012; 54 (6): 948-958.
5. Tothova Z, Wagner AJ. Anaplastic lymphoma kinase-directed therapy in inflammatory myofibroblastic tumors. *Curr Opin Oncol.* 2012; 24(4):409-413.
6. Lourenço SV, Boggio P, Simonsen Nico MM. Inflammatory myofibroblastic tumor of the tongue: report of an unusual case in a teenage patient. *Dermatol Online J.* 2012; 18(5):6.
7. Pannain VL, Passos JV, Rocha Filho A, Villela-Nogueira C, Caroli-Bottino A. Aggressive inflammatory myofibroblastic tumor of the liver with underlying schistosomiasis: A case report. *World J Gastroenterol* 2010; 16(33): 4233-4236.
8. Rao RN, Ranjan P, Singla N, Pandey R. Inflammatory myofibroblastic tumor of the urinary bladder diagnosed by anaplastic lymphoma kinase immunostaining. *Urol Ann.* 2012; 4 (2):115-118.
9. Takeuchi K, Choi YL, Togashi Y, Soda M, Hatano S, Inamura K, et al. KIF5B-ALK, a novel fusion oncokine identified by an immunohistochemistry-based diagnostic system for ALK-positive lung cancer. *Clin Cancer Res.* 2009; 15 (9) :3143-3149.
10. Binmadi NO, Packmanb H, Papadimitriouc JC, Scheper M. Oral inflammatory myofibroblastic tumor: case report and review of literature. *Open Dent J.* 2011; 5:66-70.
11. Umiker WO, Iverson L. Post inflammatory tumors of the lung; report of four cases simulating xanthoma, fibroma, or plasma cell tumor. *J Thorac Surg.* 1954; 28 (1):55-63.
12. Li J, Liu F, Wang Z, Liu Q, Wang Y, Zhou Q, et al. Inflammatory pseudotumor of the esophagus: GI image. *J Gastrointest Surg.* 2010; 14:195-198.
13. Ladd AP, Grosfeld JL. Gastrointestinal tumors in children and adolescents. *Semin Pediatr Surg.* 2006; 15 (1):37-47.
14. Mehra SK, Barolia DK, Gupta AK, Chaturvedi V. Childhood Intussusception: Timely management leads to decreased surgical risk. *Int J Innov Res Med Sci* 2018; 3: 1672-1674.
15. Zhang Y, Dong ZJ, Zhi XY, Liu L, Hu M. Inflammatory myofibroblastic tumor in lung with osteopulmonary arthropathy. *Chin Med J (Engl).* 2009;122(24):3094-3096.
16. Sanders BM, West KW, Gingalewski C, Engum S, Davis M, Grosfeld JL. Inflammatory pseudotumor of the alimentary tract: clinical and surgical experience. *J Pediatr Surg.* 2001; 36 (1):169-173.