

## Case Report

### Spontaneous caecal perforation secondary to abdominal wall abscess or vice versa - case report and review of literature

Aditya Pratap Singh,<sup>1</sup> Dinesh Kumar Barolia,<sup>2\*</sup> Harsha Vinod Bathia,<sup>3</sup> Vipal H Parmar,<sup>4</sup>  
Bhavana Asit Mehta,<sup>5</sup> Shraddha Mehta,<sup>6</sup>

1. Dr. Aditya Pratap Singh, Consultant, Department of Paediatric Surgery, Bhagwan Mahavir Hospital, Mahavir Nagar, Sumerpur, District – Pali, Rajasthan, India.
2. \*Dr. Dinesh Kumar Barolia, Department Of Paediatric Surgery, Sir Padampat Mother And Child Health Institute, S.M.S. Medical College, Jaipur, Rajasthan, India.
3. Dr. Harsha Vinod Bathia, Consultant, Department of Anaesthesia, Bhagwan Mahavir Hospital, Mahavir Nagar, Sumerpur, District – Pali, Rajasthan, India.
4. Dr. Vipal H Parmar, MD Pathology, Consultant histopathologist at neuberg supratch references laboratories, Ahmedabad, India.
5. Dr. Bhavana Asit Mehta, Head of Department Histoanatomic Pathology Department, Neuberg Supratch Reference Laboratory, Ahmedabad, Gujarat, India.
6. Dr. Shraddha Mehta, Consultant, Department Of Pathology, Bhagwan Mahavir Hospital, Mahavir Nagar, Sumerpur, District – Pali, Rajasthan, India

**Cite as:** Aditya S, Dinesh B, Harsha V, Vipal P, Bhavana M, Shraddha M. Spontaneous caecal perforation secondary to abdominal wall abscess or vice versa - case report and review of literature J Pediatr Adolesc Surg. 2020; 1: ahead

This is an open-access article distributed under the terms of the Creative Commons Attribution License, which permits unrestricted use, distribution, and reproduction in any medium, provided the original work is properly cited (<https://creativecommons.org/licenses/by/4.0/>).

## ABSTRACT

**Background:** Spontaneous caecal perforation secondary to abdominal wall abscess is a rare entity. There may be abdominal wall abscess due to spontaneous caecal perforation. Small and large bowel perforation in neonatal period is common secondary to necrotizing enterocolitis. But beyond neonatal caecal perforation is unusual.

**Case Presentation:** We are reporting an interesting case of spontaneous caecal perforation in two years old female child without any sign and symptoms of peritonitis or abdominal discomfort secondary to abdominal wall abscess. Or it may be vice versa, abdominal wall abscess develops secondary to caecal perforation.

**Conclusion:** Caecal perforation in children beyond to neonatal period is extremely rare. To the best of our knowledge, I have never seen in English literature of spontaneous caecal perforation secondary to abdominal wall abscess or vice versa.

**Keywords:** Abscess, caecal perforation, perforation, spontaneous caecal perforation

## INTRODUCTION

Caecal perforation is commonly found in beyond the paediatric age group (adult age group) secondary to inflammatory bowel disease, iatrogenic trauma, appendicitis, malignancy, diverticulitis, pseudo obstruc-

tion and lymphoma [1,2,3,4,5,6]. Various reported reasons of caecal perforation in adults after surgical procedure of other than bowel are post caesarian section, post renal transplantation, and post hernia repair [7,8,9]. Spontaneous gastrointestinal perforation is common in neonates (61.5%) and it decreases with

age in children. Colonic perforation in term infants is commonly caused by Hirschsprung disease. Necrotizing enterocolitis (NEC) is the leading cause of colonic perforation in preterm neonates [10,11]. Congenital gastrointestinal anomalies, inflammatory conditions (like necrotizing enterocolitis appendicitis, typhoid, tuberculosis, Crohn disease), iatrogenic injury, foreign body ingestion, intussusception, blunt trauma are the causes of gastrointestinal perforation in paediatric patients [12,13]. In presenting case patient had primarily anterior abdominal wall abscess. Anterior abdominal wall abscess may be due to folliculitis and progression of inflammation. But abdominal wall abscess can represent any intra-abdominal pathology like liver abscess ruptured in anterior abdominal wall, acute suppurative appendicitis or appendicular mass, and carcinoma colon [14,15]. In our case primarily abdominal wall abscess was visible. Bowel perforation was obvious after rupture of abdominal wall abscess and diagnosis of caecal perforation was made after exploration. Very few cases of caecal perforation in paediatric age groups were reported in English literature till now.

## CASE REPORT

A two years old female child admitted with complaint of fecal discharge coming out through a wound located at right hypochondriac region for two days. She was born at home by term normal vaginal delivery. The baby developed a pustule at right upper quadrant of abdomen. Pustule ruptured after three days. From the same day fecal matter was coming out from ruptured site. There was no history of fever, trauma, pain abdomen, constipation, diarrhea or blood in stool. There was no history previous consultation and surgical intervention. On clinical examination, she was poorly nourished baby. She was alert and active according to age. There was no pallor, icterus or palpable lymph node anywhere. A 2 x 2 cm size wound was present at right hypochondriac region surrounding by red erythematous skin contaminated with fecal matter (Fig 1). All the routine blood and radiological investigation were done. The patient was optimized, and we proceeded for exploration. On exploration, peritoneal cavity was clean, no sign of fecal contamination. But the caecum was adhered to anterior abdominal wall. Adhesion of caecum with abdominal wall was released. There was a perforation in the cecum approximately 2 cm distal to base of appendix and it was adhered to anterior abdominal wall. Appendix appeared normal (Fig 2). We did appendectomy and repair of caecal perforation in two layers. The entero-cutaneous fistula site and laparotomy site was repaired in layers. After post-operative day three she passed stool. Oral feed started on post-operative day six. Both wounds stayed healthy. She was discharged on post-operative day

seven. On serial Follow-up's patient developed no complications.

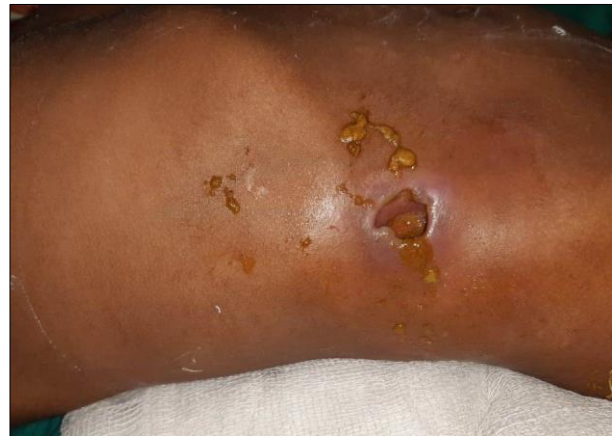

Figure 1: Fecal Discharge from Abdominal wall Abscess

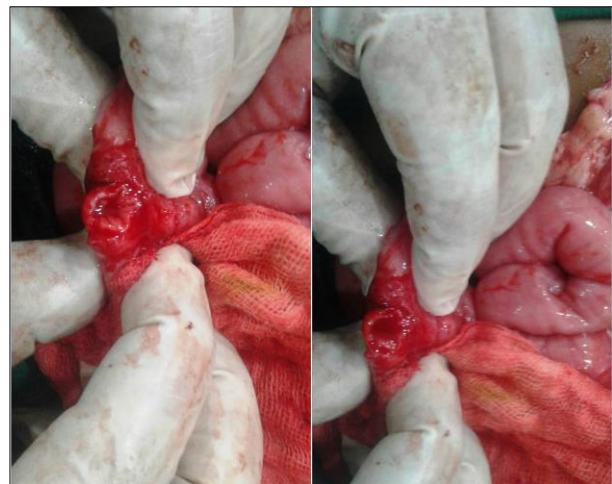


Figure 2: Perforation in Cecum

## DISCUSSION

Gastrointestinal perforations have so many causes and present a challenge to paediatric surgeons. Neonates and infants cannot give their own history and older children are seldom helpful in this matter as well. Here we are discussing this case because there were no sign and symptom of bowel perforation. There were no sign of peritonitis. She had simply an abdominal wall abscess formation at right upper quadrant of abdomen and ruptured spontaneously after three days and surprisingly fecal matter coming out from ruptured abscess site. Very few cases of spontaneous caecal perforation were reported in paediatric patients. Reported cases of caecal perforation in paediatric patients (table 1) had diarrhoea with fever, impacted faecolith, acute gastroenteritis, and as a complication of appendicitis [16,17,18,19,20].

Spontaneous colonic perforation is classified in two groups (a) idiopathic (b) stercoral. This classification

was given in 1984 by J.A. Berry. He classified on the basis of etio-pathological causes lesions. Stercoral perforation shows colonic inflammation, ulcer and necrosis. Idiopathic spontaneous perforation shows minimal or no fecal contamination, linear tear and normal appearing colonic wall [21,22,23]. The criteria for stercoral colonic perforation is a perforation which is more than 1 cm in diameter at anti-mesenteric border, with fecal contamination of peritoneal cavity, perforation site and gut. There may be ulcer, chronic inflammation, necrosis at or around the perforation site. However, we have to exclude obstruction, tumors, external injury, and diverticulosis. This criterion was given by Maurer CA et al in 2000 [24].

Table 1: Showing reported cases of caecal perforation in paediatric patients

Sr. No.	Reference Year	Age	Gender	Cecal perforation secondary to
1.	E.D. Sy et al. 2001 [11]	2 y	Male	Diarrhoea and fever
2.	VL Simpkin et al. 2009 [12]	11y	Male	Faecolith impaction
3.	Duvuru Rama et al. 2014 [13]	15y	Male	Acute fulminant gastroenteritis
4.	Calista Harbaugh et al. 2016 [14]	16y	Male	Secondary to bacterial infection
5.	Ravi Shankar J C et al. 2016 [15]	19y	Female	Secondary to appendicitis
6.	Dinesh Kumar Barolia	2y	Female	Secondary to abdominal wall abscess or vice versa

Various reported causes of Spontaneous caecal perforation are trauma, malignant obstruction, Impaction of foreign bodies in caecum, volvulus, inflammatory bowel conditions, and bowel infection [25]. Perforation

**REFERENCES**

- Greenstein AJ, Sachar DB, Mann D, Lachman P, Heimann T, Aufses AH Jr. Spontaneous free perforation and perforated abscess in 30 patients with Crohn's disease. *Ann Surg*1987; 205:72-6.
- Luning TH, Keemers-Gels ME, Barendregt WB, Tan AC, Rosman C. Colonoscopic perforations: A review of 30,336 patients. *Surg Endosc* 2007; 21:994-7.
- Wong CS, Naqvi SA. Appendicular perforation at the base of the caecum, a rare operative challenge in acute appendicitis, a literature review. *World J Emerg Surg.* 2011; 6:36.
- Yanchar NL, Bass J. Poor outcome of gastrointestinal perforations associated with

of healthy caecum is rare. Various different possible mechanisms were explained in different articles. VL Simpkin et al. reported a case of caecal perforation in 11 years old male child in 2009 due to impaction of faecolith. Impacted faecolith in caecum causes distension and stretching of caecal wall and perforation occurred [17]. Dehydration or inadequate hydration is a risk factor associated with non-typhoid Salmonella infection leads to bowel perforation. Severe dehydration can leads to bowel ischemia and cause perforation. Spontaneous caecal perforation is the complication of fulminant gastroenteritis in children [18,26]. Primary appendicitis can cause periappendicitis. Periappendicitis leads to caecal inflammation and cause posterior caecal wall perforation [20].

Probably in our case the abdominal wall abscess could cause adhesion of caecum at the deep site of abdominal wall abscess. Further due to inflammatory reaction adhere caecal wall became oedematous and pyogenic microorganism could perforation and fecal fistula formation occurred. Early surgery is indicated in spontaneous enterocutaneous fistula. Peritoneal contamination is not found in such cases [27]. We did double layer repair of perforation. The follow-up period was peaceful for parents and pleasant for patient.

In conclusion, Perforation of apparently healthy caecum is very uncommon. Very few cases were reported in English literature of spontaneous perforation of caecum in paediatric age group. Exploration and restoration of continuity is the treatment of choice.

**Acknowledgements:** Nil.

**Conflict of Interest:** None.

**Consent to Publication:** Author(s) declared taking informed written consent for the publication of clinical photographs / material (if any used), from the legal guardian of the patient with an understanding that every effort will be made to conceal the identity of the patient, however it cannot be guaranteed.

**Authors Contribution:** Author(s) declared to fulfill authorship criteria as devised by ICMJE and approved the final version.

- childhood abdominal non-Hodgkin's lymphoma. *J Pediatr Surg* 1999; 34:1169-74.
- Griffiths EA, Date RS. Acute presentation of a solitary caecal diverticulum: A case report. *J Med Case Reports* 2007; 1:129.
- Spira IA, Wolff WI. Gangrene and spontaneous perforation of the cecum as a complication of pseudo-obstruction of the colon: report of three cases and speculation as to etiology. *Dis Colon Rectum.*1976; 19 (6):557-62.
- Laskin MD, Tessler K, Kives S. Cecal perforation due to paralytic ileus following primary caesarean section. *J Obstet Gynaecol Can.* 2009; 31:167-71.

8. Puglisi BS, Kauffman HM, Stewart ET, Dodds WT, Adams MB and Komorowski RA. Colonic Perforation in Renal Transplant Patients. *AJR. Am J Roentgenol.* 1985; 145 (3), 555-58.
9. Yeo R. Spontaneous perforation of the caecum: case reports and a review of the literature. *Postgraduate Medic J.* 1967; 43(495):65-7.
10. Singh S, Rawat J, Wakhlu A, Kureel SN, Pandey A. Six-year retrospective analysis of colonic perforation in neonates and infants: Single centre experience. *Afr J Paediatr Surg* 2012;9: 102-5.
11. Yu L, Tian J, Zhao X, Cheng P, Chen X, Yu Y, et al. Bowel perforation in premature infants with necrotizing enterocolitis: Risk factors and outcomes. *Gastroenterol Res Pract* 2016;2016:6134187
12. Cruze K, Snyder WH., Jr Acute perforation of the alimentary tract in infancy and childhood. *Ann Surg.* 1961;154:93-99.
13. Stevenson RJ. Abdominal pain unrelated to trauma. *Surg Clin North Am.* 1985;65: 1181-1215.
14. Mohamed IS, Hodi SCA, Baker NA, Zakaria Z. Anterior abdominal abscess as a complication of appendicular mass in elderly. *Trop Med Surg* 2013; 1(5):137.
15. Andaz S, Heald RJ. Abdominal wall abscess an unusual primary presentation of a transverse colonic carcinoma. *Postgrad Med J* 1993;69: 826-28.
16. Sy ED, Liu CS, Huang SM, Shan YS. Cecal perforation presenting as abdominal-wall necrotizing fasciitis. *Pediatr Surg Int* 2001; 17:215-217.
17. Simpkin V L, Lakhoo K. An unusual cause of caecal perforation in a child. *Afr J Paediatr Surg* 2009; 6:114-115.
18. Ram D, Karthikeyan, V S, Sistla, S C, Ali S M, Sridhar P, Rajkumar N. Spontaneous cecal perforation secondary to acute fulminant gastroenteritis: report of a rare case, *Annals of Pediatric Surgery: January 2014 - Volume 10 - Issue 1 - p 12-13.* doi: 10.1097/01.XPS.0000437373.44829.cb
19. Harbaugh C, Siddiqui S, Sutherland C, Rabah-Hammad R, Hirschl. Case report of idiopathic cecal perforation presenting as acute appendicitis on ultrasound. *J Pediatr Surg Case Rep* 2016; 11:28-30.
20. Ravi Shankar J C, Narayan Hebsur, Hosmani Ramesh, K N Praveen and Kumar Abhishek. Cecal Perforation Secondary to Appendicitis-But not at the Base of Appendix. *World J Med Surg Case Rep* 2016; 5:1-4.
21. Al Shukry S. Spontaneous perforation of the colon: clinical review of five episodes in four patients. *Oman Med J.* 2009;24:137-41.
22. Velitchkov NG, Kjossev KT, Losanoff JE, Grigorov GI, Kavardjikova-Milanova VA. Stercoral perforation of the colon. *Rozhl Chir* 1995. Apr;74(3):145-146.
23. Basile M, Montini F, Cipollone G, Errichi BM. Spontaneous perforations of the large intestine. *Ann Ital Chir* 1992. Sep-Oct;63(5):625-629.
24. Maurer CA, Renzulli P, Mazzucchelli L, Egger B, Seiler CA, Buchler MW. Use of accurate diagnostic criteria may increase incidence of stercoral perforation of the colon. *Diseases of the colon and rectum.* 2000;43: 991-8.
25. Yeo R. Spontaneous perforation of the caecum: case reports and a review of the literature. *Postgrad Med J* 1967; 43:65-67.
26. Chao HC, Chiu CH, Kong MS, Chang LY, Huang YC, Lin TY, Lou CC. Factors associated with intestinal perforation in children's non-typhi Salmonella toxic megacolon. *Pediatr Infect Dis J* 2000; 19:1158-1162.
27. Diyya G, Debnath PR, Kundal VK, Kumar A, Kumar A, Sen A. Spontaneous enterocutaneous fistula in an infant. *J Pediatr Adolesc Surg.* 2020; 1: ahead.